

EM CARE

Towards saving lives and bringing hope



Spreading... SMILE

Partnering States and Union Territories



Towards Saving Lives and Bringing Hope...

Launched on 15th August 2005 in Hyderabad and expanded
to 17 States and 1 Union Territory in India



89,368 CALLS ANSWERED EVERY DAY



39,254 EMERGENCIES RESPONDED PER DAY FLEET OF 9,774 AMBULANCES BY TRAVELLING DISTANCE OF 15.61 Lakhs KM PER DAY
35.32 Lakhs EMERGENCIES RESPONDED FOR (OCT-DEC 2025)



83.38 Lakhs LIVES SAVED AND 6.91 Lakhs DELIVERIES ASSISTED BY EMTs SINCE INCEPTION



"ENHANCING HEALTHCARE EXCELLENCE: EMRI GHS INITIATIVES AND MILESTONES"

Dear Team,

EMRI Green Health Services had a remarkable Q3 in 2025, marked by numerous national-level events that underscored its commitment to enhancing healthcare services across India.

October 2025 was a notable month for EMRI GHS, with the organization receiving the BSNL Most Valued Customer Award on 1st October. The team was honored with the 'Excellence in Life Saving Services' Award on 16th October, recognizing their outstanding contribution to emergency healthcare. CPR Awareness week observed during 13-17 Oct 2025 on instructions of MOHFW, GOI. During this period, CPR demo sessions were conducted across EMRI operating states. Diwali Celebrations were held on 18th October. The month also saw the Annual Reward and Recognition Program at Uttar Pradesh on 9th October, and an Appreciation Letter from the Hon'ble Health Minister of Assam for 17 years of Mrityunjay 108 Emergency Ambulance services. EMRI GHS has renewed its affiliation as a Comprehensive Resuscitation Training Centre (CRTC) with the Indian Resuscitation Council Federation (IRCF) for 2 years, effective from 6 October 2025 to 6 October 2027. As a CRTC, EMRI GHS is now authorized to conduct training programs in Basic Cardiopulmonary Life Support (BCLS), Comprehensive Cardiopulmonary Life Support (CCLS), and Compressions Only Life Support (COLS).

November 2025 witnessed significant milestones, including the launch of 90 New 108 Ambulances by Hon'ble Chief Minister of Tamil Nadu Shri. M.K. Stalin on 1st November. The organization also conducted a Knowledge Forum for AI Tools on 12th November. The Annual Reward and Recognition Program was held at Gujarat on 21st November, and EMRI GHS Karnataka State Head Shri. Hanumanthappa received the Karnataka Seva Rthna Award on 22nd November. A Certification Program on ASLS for National EMS Trainers by Angels Initiative held on 28th November 2025.

December 2025 was a busy month, with the *Leadership Workshop*, "Shaping the next decade: Growth through operational excellence and innovation" held in 18-20 December 2025. 56-participants including national leadership, SHOs, functional leaders and domain experts were part of the workshop. Professor Ravi Anupindi, Michigan, USA launched 3 Mobile Bike Workshops in Telangana state on 20th December. The month also saw the launch of 420 New 108 Ambulances by Hon'ble Chief Minister of Odisha Shri Mohan Charan Majhi on 23rd December. Additionally, a Fusion Training program was conducted at Gujarat on 23rd and 24th December, and an MOU was signed for Ambulance Services at Puri Jagannath Temple on 29th December.

EMRI Green Health Services (EMRI-GHS), Hyderabad, India, has renewed its Service Agreement with Stanford University's School of Medicine, Department of Emergency Medicine, for a term of 4 years, this agreement solidifies the partnership between the two institutions, likely focusing on collaborative efforts in emergency medicine and healthcare services. Special Health Day messages were prepared and disseminated among EMRItes on World Stroke Day on 29th October 2025, World Diabetes Day on 14th November 2025, World Remembrance Day for road traffic victims on 16th November 2025.

I extend my heartfelt congratulations to the exceptional teams of Gujarat for October 2025, Tamil Nadu for November 2025 and Telangana for December 2025 for receiving the Life Saviours Award. Your unwavering dedication and commitment to saving lives have made a remarkable impact, and this recognition is a testament to your exceptional work.



With best wishes

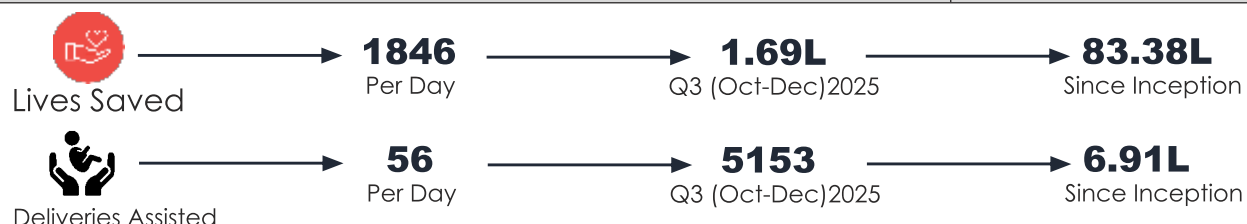
K. Krishnam Raju

DIRECTOR - EMRI Green Health Services



Physical Progress

S.No	Name of the State Government	No of Ambulance as on December 25	Emergencies Since Inception	Emergencies Attended in Q3 (Oct'25-Dec'25)
1	Telangana	626	103.8 Lakhs	1.99 Lakhs
2	Gujarat	1442	187.15 Lakhs	4.25 Lakhs
3	Goa	103	9.52 Lakhs	0.22 Lakhs
4	Tamil Nadu	1,394	191.78 Lakhs	4.73 Lakhs
5	Karnataka	715	120.22 Lakhs	1.24 Lakhs
6	Assam	799	72.86 Lakhs	0.81 Lakhs
7	Diu Daman & Dadra Nagar Haveli	22	5.01 Lakhs	0.11 Lakhs
8	Uttar Pradesh	2,200	443.4 Lakhs	16.51 Lakhs
9	Rajasthan	1,094	62.57 Lakhs	1.49 Lakhs
10	Kerala	316	12.32 Lakhs	0.54 Lakhs
11	Delhi	87	20.49 Lakhs	0.35 Lakhs
12	Arunachal Pradesh	110	0.36 Lakhs	0.02 Lakhs
13	Odisha	866	16.04 Lakhs	3.06 Lakhs
	Q3 FY-2025-26	9,774	1206.02 Lakhs	35.33 Lakhs
Average Emergencies Attended Per Day				0.38 Lakhs

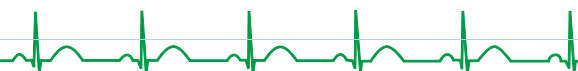

Janani Shishu Suraksha Karyakram (Mother & Child)

S. No	Name of the State Government	No of Janani Ambulance as on December 2025	Janani Beneficiaries Since Inception	Janani Beneficiaries in Q3 (Oct'25-Dec'25)
1	Gujarat	434	142.04 Lakhs	4.59 Lakhs
2	Telangana	300	81.78 Lakhs	2.39 Lakhs
3	Uttar Pradesh	2,270	1099.36 Lakhs	41.42 Lakhs
4	Goa	4	0.11 Lakhs	238
5	West Bengal	800	55.77 Lakhs	2.07 Lakhs
6	Tamilnadu	130	22.9 Lakhs	0.9 Lakhs
7	Odisha	500	4.51 Lakhs	1.14 Lakhs
	Q3 Total	4,438	1406.47 Lakhs	52.51 Lakhs
Average Emergencies Attended Per Day				0.57 Lakhs

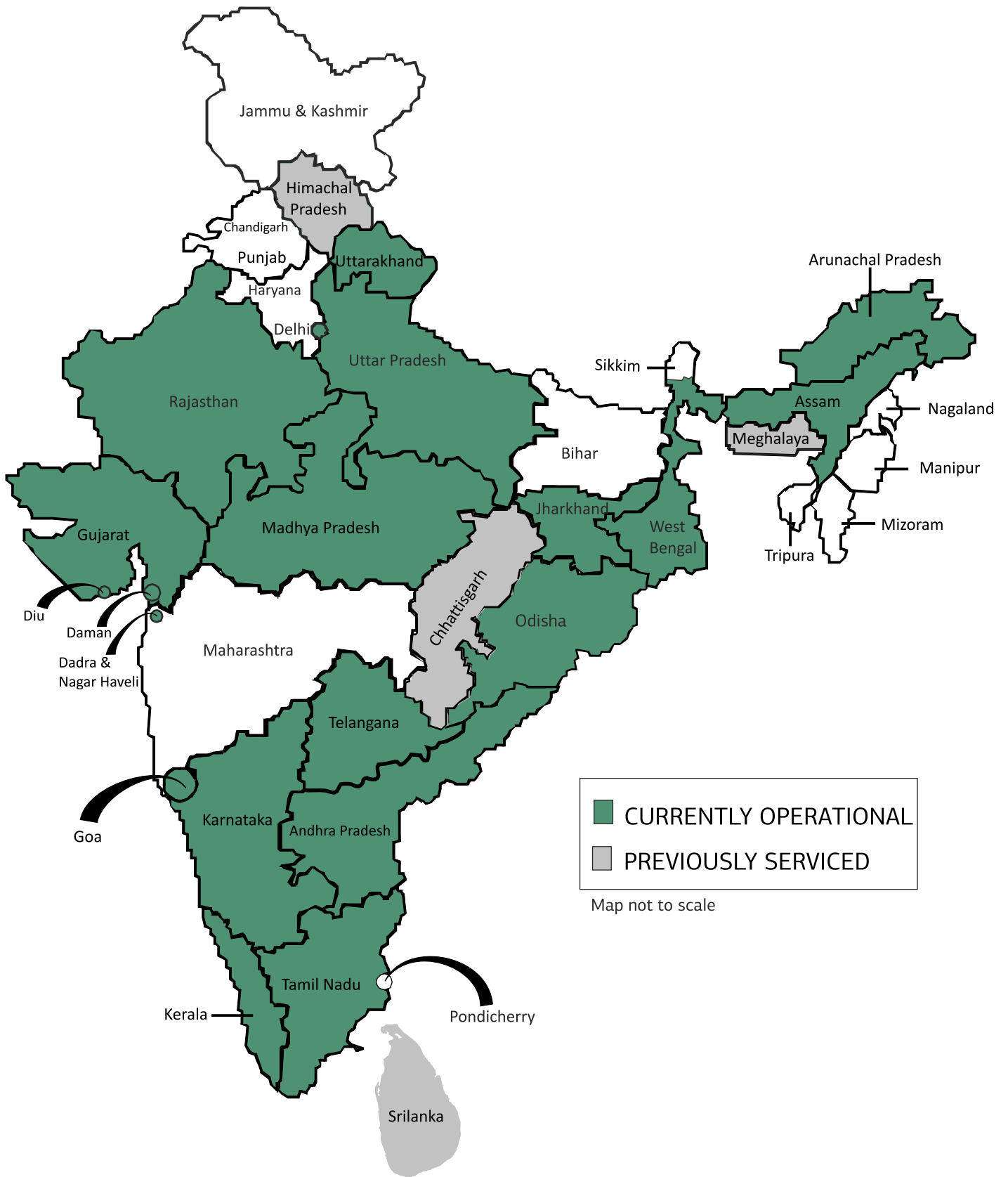
“Over the tenure spanning from 2008 to 2025, the **108** completed projects across 8 states collectively handled more than **1.66 crore emergencies**, assisted over **1.43 lakh deliveries**, and helped **save 6.5 lakh Lives** - underscoring EMRI's enduring contribution to lifesaving care across India.”

“Between 2014 and 2023, the JSSK projects completed across **3 states** supported **over 97 lakh mothers and children**, ensuring safer access to healthcare and reinforcing EMRI's commitment to maternal & child well-being across states.”





- 108 Emergency Response Center handles over 250,000 calls daily.
- An impressive 97% of calls are answered within just 2 rings.
- Initiated to lower neonatal mortality rates.
- Fully equipped (incubator- ventilator etc.) to facilitate the transfer of newborns between Special Newborn Care Units (SNCU) and Neonatal Intensive Care Units (NICU).
- Initiated to reduce infant and maternal mortality rates
- These ambulances are designed to transport pregnant women, mothers and newborn babies from home to hospital and hospital to home in sterile and safe environment
- Mobile Medical Units(MMU) provide primary health care on wheels.
- Serve medical needs of individuals in remote areas
- Introduced for rapid response to medical emergencies in riverine regions.
- Provide critical healthcare support during floods
- Primarily used to transit care patients from lower level to higher level hospitals in emergency situations.
- This innovative approach is designed to carry emergency patients navigate hilly terrains or no road connectivity
- Health helpline services in non-emergency
- This telemedicine service offers information, advice, and counseling
- Implements "Dial 100 Police" service to combat crime and maintain societal peace and safety
- It uses advanced technology to analyze calls, enhance information for rapid response, facilitate follow-up and expedite information sharing to different levels of law enforcement & prompt response.
- "Call 181" - Women Helpline is a dedicated service aimed at assisting women in distress
- Mobile Veterinary Units accessed through 1962 toll free no. provides doorstep point-of-contact- care (POCC) for livestock and stray animals.
- MVUs with Hydraulic lift to carry animals to veterinary facilities in few states





108 Saviour of EMRI GHS - INDIA

OCTOBER 2025	: GUJARAT TEAM – A CASE OF MEDICAL EMERGENCY	08
NOVEMBER 2025	: TAMIL NADU TEAM – A CASE OF BURNS	17
DECEMBER 2025	: TELANGANA TEAM – A CASE OF WORK PLACE ACCIDENT	26

STATE WISE CASE OF THE MONTH

OCTOBER	: ASSAM TEAM – A CASE OF MEDICAL EMERGENCY	09
OCTOBER	: GOA TEAM – A CASE OF RTA	10
OCTOBER	: KARNATAKA TEAM – A CASE OF RTA	11
OCTOBER	: KERALA TEAM – A CASE OF RTA	12
OCTOBER	: TAMIL NADU TEAM – A CASE OF RTA	13
OCTOBER	: TELANGANA TEAM – A CASE OF TRAIN ACCIDENT	14
OCTOBER	: UTTAR PRADESH TEAM – A CASE OF BURNS – MCI	15
NOVEMBER	: GOA TEAM – A CASE OF MEDICAL EMERGENCY	18
NOVEMBER	: GUJARAT TEAM – A CASE OF COMPLICATION IN PREGANCY	19
NOVEMBER	: KARNATAKA TEAM – A CASE OF RTA	20
NOVEMBER	: KERALA TEAM – A CASE OF ASSAULT	21
NOVEMBER	: TELANGANA TEAM – A CASE OF ELECTROCUTION	22
NOVEMBER	: UTTAR PRADESH TEAM – A CASE OF MEDICAL EMERGENCY	23
DECEMBER	: GOA TEAM – A CASE OF MEDICAL EMERGENCY	26
DECEMBER	: GUJARAT TEAM – A CASE OF COMPLICATED DELIVERY	27
DECEMBER	: KARNATAKA TEAM – A CASE OF RTA	28
DECEMBER	: TAMIL NADU TEAM – A CASE OF RTA	29
DECEMBER	: UTTAR PRADESH TEAM – A CASE OF RTA – MCI	30

NOT FOR PROFIT ORGANISATION OPERATING IN PUBLIC PRIVATE PARTNERSHIP MODEL



A CASE OF MEDICAL EMERGENCY

OCTOBER 2025

Details of the incident:

On 14th October, 2025, our Deesa location team received a call from the Medical Officer of SDH Deesa for 12-year-old Jigarbhai, a resident of Banaskantha district who had multiple episodes of convulsions and also had a history of convulsions & Mitral Regurgitation since childhood. EMT Shamlabhai Parmar requested the Medical Officer to keep his medical records ready for seamless handover.

Diagnosis or condition:

On arrival at the scene, the doctor informed EMT that the patient's condition was very critical, his Hb was only 4.2 gm/dl & he needed to be kept on ventilator support. At SDH, the Medical Officer had administered Inj. Midazolam, Inj. Phenytoin, and Inj. Cefotaxim and kept on Oxygen. EMT found that the patient was in an Unconscious State with hypoxia, bradycardia and blood pressure was not recordable. As per the IFT protocols, EMT contacted ERCP Dr Trivedi to obtain ERCP approval for this transfer, and thereafter, EMT immediately transferred Jigarbhai into the ambulance with the help of Pilot Dalpatbhai Parmar and relatives.

Pre-hospital management:

After transferring him into the ambulance,

the EMT promptly suctioned his airway, maintained it with Naso Pharyngeal Airway and started bag valve mask ventilations with high flow oxygenation. EMT assessed the vital signs of the patient, which were as follows: Pulse Rate 42 beats/min, SpO2 88%, Respiration Rate 18 breaths/min, Capillary Refill time was more than 2 sec and Blood Pressure was not recordable. Suddenly, the patient started convulsing, and EMT immediately contacted ERCP Dr Trivedi, and as per his advice, EMT administered Inj. Midazolam, suctioned his airway intermittently & continued Oxygenation. After 10-15 minutes, on reassessment, it was found that the patient went into Cardiac Arrest, and thus, EMT requested Pilot to stop the ambulance and asked for his help. EMT started Cardio Pulmonary Resuscitation and requested Pilot to apply AED pads on the patient's chest. After rhythm analysis, the AED machine advised for shock, and accordingly, the EMT delivered shock and then resumed CPR. EMT immediately contacted ERCP Dr Krushna, and as per her advice, EMT administered Inj. Adrenaline and Inj. Atropine. After 2 minutes of CPR, the AED machine again advised for shock & hence the EMT delivered shock once again, followed by resuming CPR. As EMT noticed

return of spontaneous circulation, he stopped CPR but continued BVM ventilation with high flow oxygenation for severe hypoxia, whereas the Pilot restarted the Ambulance's journey towards the Hospital. EMT re-assessed vital signs, which were as follows: SpO2 82%, Respiration Rate 24 breaths/min, Pulse Rate 66 beats/min, Pupils were B/L constricted, RBS 108 mg/dl and BP were not recordable. EMT again contacted ERCP - Dr Krushna and as per her advice, EMT administered IV RL 500 ml and continued BVM ventilations. EMT also kept reassuring the patient's relatives as they were very anxious & distressed.

Patient's condition at the time of handing over:

After implementing all necessary interventions and with continuous monitoring, the patient was shifted to GMERS Medical Hospital, Dharpur, Patan, after travelling for 65 km. At the time of handing over, the patient's condition had shown some improvement.

Reflection of the patient or the patient's relative:

The relatives tremendously appreciated the care given by the EMT and Pilot which eventually saved this patient's life.



REFLECTION BY EMT : SHAMLABHAI PARMAR

"I am extremely happy to have been selected as the Saviour for the first time. I am also thankful for the privilege of being able to save a life. I am really thankful to EMRI Green Health Services for giving me this opportunity to serve. I also thank my Pilot Dalpatbhai Parmar, for helping me in this life-saving mission. Lastly, I thank the EMLC Team who equipped me with the necessary knowledge & skills, without which this mission of saving life wouldn't have been possible."

REFLECTION BY PILOT : DALPATBHAI PARMAR

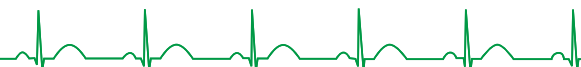"I am really happy to work with EMT Shamlabhai Parmar, especially in challenging situations. I thank all who have given me this nice opportunity to serve my fellow human beings. This gives me lots of satisfaction."



CASE DETAILS

PATIENT RECEIVING PRE-HOSPITAL CARE IN 108 AMBULANCE, MEDIA CLIPPING & APPRECIATION LETTER

AMBULANCE LOCATION : DEESA
 CASE ID : 20251000122663
 DATE : 14/10/2025
 CALL TIME : 12:20 HRS
 ERCP : Dr. TRIVEDI & DR. KRUSHNA
 RECEIVING HOSPITAL : GMERS MEDICAL COLLEGE AND HOSPITAL, DHARPUR, PATAN



Details of the incident:

The call was received on 10th Oct 2025, at the ERC requesting the 108 Ambulance service for a 16-year-old boy, Mofidul Islam. Receiving the case, ERO assigned the case to the Chapar Block Location of Dhubri District. Sensing the situation, EMT Raj Kumar Saha quickly took details of the case and became active and prepared for the case. Pilot Tilak Kr. Ray rushed the Ambulance towards the scene.

Diagnosis or condition:

On reaching the scene, EMT found that a young boy was in a semiconscious state, having breathing difficulties and in critical condition, so EMT immediately assessed the patient and took the history and found that Mofidul was diagnosed with epilepsy at a young

age and had his first seizure when he was 4 years old. He had experienced frequent seizures and required constant supervision due to the unpredictable nature of his seizures. On 10th Oct, in the evening, he had a severe seizure and fainted. Immediately, the EMT took the patient to the ambulance with the help of my co-Pilot.

Pre-Hospital Management:

At the scene, vitals were monitored by EMT and recorded BP- 115/65 mm Hg, PR-70 Bpm, RR-20/minutes, SPO2-92 %. EMT placed the patient in a lateral position and took ERCP advice from Dr Anupam Borgohain. According to ERCP advice, EMT maintained the airway and administered Oxygen immediately.

Patient condition at the time of handover:

After providing oxygen, Enroute EMT kept constant monitoring on the patient until they reached the hospital. Before reaching the hospital, the patient had improved a lot. and Oxygen saturation returned to normal. En route to the hospital, vitals were recorded as BP-135/70 mm Hg, PR-21 Bpm, RR 21/minutes, SPO2-96 %, he was handed over to Santoshpur SC.

Reflection of the patient or patient relative:

The Patient was in critical condition. The medical staff on duty and the relatives of the patient appreciated and praised the team for saving the life of such a critical case.



REFLECTION BY EMT : RAJ KUMAR SAHA

"It always gives great pleasure to help those who are in distress and need. The advice of the ERCP doctor helped me a lot to give immediate relief to the patient using the medicines advised by the ERCP. The attendant appreciates us for the generosity provided to the patient."

REFLECTION BY PILOT : TILAK KR RAY

"Completing the role and responsibility of a pilot, I always give my full support to the EMT during the care of the patient. And help to hand over the patient to the hospital swiftly and in time."



CASE DETAILS

PATIENT RECEIVING PRE-HOSPITAL CARE IN 108 AMBULANCE & MEDIA CLIPPING

AMBULANCE LOCATION : CHAPAR BLOCK, DHUBRI
 CASE ID : 20251000059264
 DATE : 10/10/2025
 CALL TIME : 7: 27 HRS
 ERCP : Dr. ANUPAM BORGHAIN
 RECEIVING HOSPITAL : SANTOSH PUR SC



A CASE OF RTA

OCTOBER 2025

Details of the incident:

On 23rd Oct 2025 at 9:37 Hrs., our emergency response center received a call from Chowgum road, Porvorim, stating that there was a self-road traffic accident of a 2-wheeler. Porvorim ambulance was the nearest available ambulance. After taking scene details, the EMT and Pilot rushed to the scene with the relevant equipment to provide necessary Pre-hospital care. En route towards the scene, EMT advised the caller to control any external bleeding of the patient with direct pressure and not to feed him anything orally. Ensuring scene safety and maintaining BSI precautions, our team arrived on the scene.

Diagnosis or condition:

After assessing scene safety, EMT

and the Pilot approached patient. On arrival at the scene, the patient was found semi-conscious and oriented. The patient was having a right leg Ankle region open wound with heavy bleeding, along with exposed tissues. EMT began a quick trauma survey. The patient was a 62-year-old male. Immediately, wound care was given to the patient, and external bleeding was controlled. A splint was applied to the affected extremity.

Pre-hospital management:

The patient was shifted in the ambulance on a spine board. Without wasting time, EMT recorded vitals. Initial assessment revealed vital signs: BP 120/80 mmHg, Pulse 90 bpm, Respiratory Rate 22 breath/min, SpO₂ 99%. The patient was in severe pain. EMT

called ERCP. Dr Asif was on duty and advised IV Access, Splinting, Wound Care, Comfortable Position, Inj. NS (100 ml) and Inj. Tramadol was prescribed to the patient who was in severe pain. EMT gave all the advised prehospital care to the patient as per ERCP.

Patient condition at the time of handing over:

After implementing the necessary interventions and continuously monitoring the patient, the EMT observed an improvement in the patient's condition. The EMT gave reassurance to the patient. Meanwhile, the ambulance reached the destination hospital. The patient was handed over to the casualty department of the GMC.

Reflection of the patient:

Thank you to the ambulance team



REFLECTION BY EMT : UJWALA SHANKAR KAMBLE

"It was a challenging case, and we took extra care while handling this particular victim. The victim's injury was bleeding severely when we arrived at the scene. Provided Pre-Hospital Care to the victim on scene and immobilized the injured extremity by proper skills, which we have learnt in our Refresher training programs and saved the victim's life."

REFLECTION BY PILOT : SHUBHAM BHAGWAN SATELKAR

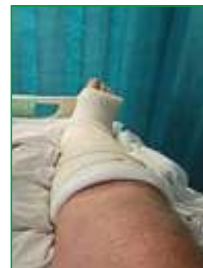"We provided the required pre-hospital care to the patient by following all protocols and transferred the patient on time to the hospital, thereby saving the victim's life. Thanking GVK EMRI GHS for allowing me to save the lives of others."



CASE DETAILS

PATIENT RECEIVING PRE-HOSPITAL CARE IN 108 AMBULANCES

AMBULANCE LOCATION : PORVORIM PHC, NORTH GOA
 CASE ID : 20251000020034
 DATE : 23/10/2025
 CALL TIME : 09:37 HRS
 ERCP : Dr. ASIF
 RECEIVING HOSPITAL : GMC



OCTOBER 2025

A CASE OF RTA

Details of the incident:

On 22nd October 2025 at 08:39 Hrs., Emergency Response Center (ERC) received a call from a good Samaritan from Gokak Taluk Dam main road signal of Belgum District, who was very frightened and requested an ambulance urgently. On asking about case details, our Emergency Response Officer (ERO) stated that the victim was 40yr, met with a two-wheeler accident. The nearest available ambulance was at the Gokak govt hospital location, which had just then completed a case and had made a release call (R Call) to ERC stating that they were ready for the next case. The case was immediately assigned to an ambulance with EMT Ms Laxmi and Pilot Shankar on duty, and the location, which was 5 km's away within 08 minutes of duration.

Diagnosis or condition:

When the 108-crew reached the scene, EMT found that the victim was a 40-year-old male, a drunken victim who had a right long bone & lower leg fracture, Right elbow open fracture and irregular

laceration with severe bleeding. EMT assessed and found that the patient was conscious & alert. The victim was shifted into the ambulance using SMRD and assessed for bleeding and controlled with direct pressure

Pre-hospital management:

EMT Ms Laxmi realized the emergency condition and shifted the victim immediately into the ambulance with the right leg & right hand padded adequately and splinted. Meanwhile, she had instructed Pilot. Shankar is to be prepared to shift the victim to a nearby medical facility.

EMT applied large pads covered the wound, then a long splint to the right leg and a short splint to the hand. Before and after splinting, PMS were checked. At the right lateral of the body, lacerated wounds were treated. IV line was accessed and started fluid RL at 60/drops/minute. Base line vitals were recorded, BP-110/70mmof Hg, Pulse-104/bpm, RR-26 breaths/min, SPO2-92%, victim was diaphoretic &

agitated. On consultation with ERCP Dr. Monika, oxygen was started at 6 lts/min & shifted to the nearest hospital.

Patient condition at the time of handing over:

Hospital doctors appreciated EMT & Pilot for their presence of mind and the accurate pre-hospital management which was given to the victim on scene & in the ambulance before reaching to the hospital. The victim was immediately attended by a Team of Doctors for further evaluation of the victim's condition.

EMT Mr Laxmi & Pilot Mr Shankar returned the victim's Rs 6000 & Mobile phone to his family member at the hospital honestly.

Reflection of the patient or patient relative:

Victim's brother showered blessings and his gratitude towards our ambulance team. The condition of the victim was stable during the 48-hour follow-up call. The victim was shifted to the higher facility center for further surgical care.



REFLECTION BY EMT : LAXMI

"It was a very challenging case for me, and I felt very much satisfied after shifting the victim to the hospital within the golden hour. It gives tremendous pleasure to serve people when they are in need of our help & support. I am thankful to EMRI GHS for giving me an opportunity to save the life of a needy person. Honesty & integrity are the best essence of a satisfied life, which I felt after handing over their valuables, which the family received with huge gratitude."

REFLECTION BY PILOT : SHANKAR

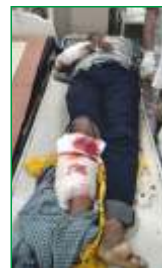"I am happy because I took part in Pre-Hospital Care & I was able to shift the patient on time to the hospital, which made the work of doctors and other staff to treat effectively, and I would like to say thanks to EMRI GHS for giving me an opportunity to work as a Pilot in 108 Ambulance to serve the community."



CASE DETAILS

PATIENT RECEIVING PRE-HOSPITAL CARE IN 108 AMBULANCES

AMBULANCE LOCATION : GOKAK GOVT HOSPITAL
 CASE ID : 3137297
 DATE : 22/10/2025
 CALL TIME : 08:39 HRS
 ERCP : Dr. MONIKA
 RECEIVING HOSPITAL : ATHARVA HOSPITAL



A CASE OF RTA

OCTOBER 2025

Details of the incident:

Feroke Thqh ambulance was dispatched to respond to a call regarding a 4-Wheeler Accident, a speeding car hit the rear side of a parked tourist bus along the road. The incident occurred at Ramanattukara at approximately 07:38 Hrs. The ambulance reached the scene within 04 minutes of receiving the call.

Diagnosis or condition:

The EMT quickly assessed the condition of the patients. The First patient, Ms Sinan, a 20-year-old female, was in altered mental status (V) and disoriented, and had ear and nose bleeding, bleeding from the genital area, a fall led to breathlessness, fracture of the right humerus bone and dislocation of the right femur bone and the EMT suspected spinal injury and pelvis injury. The second patient, Ms Lamia, an 18-year-old female, was conscious and oriented. An open wound is present in the right thigh and is

suspected of head injury and fracture of the right femur bone.

Pre-hospital management:

The patients were immediately shifted into the ambulance with the help of a spine board, and EMT quickly started to provide pre-hospital care, such as proper positioning to restrict the movements. Checked the vitals of the first victim, temperature 98.6F, BP 100/60 mm of Hg, Pulse 52 bpm, RR16 breath/minutes and Spo₂90% and based on this, EMT assessed that the patient is in hypotension. EMT quickly administered oxygen at 7L per hrs. and IVF NS 500ml bolus. Second victim vitals were temperature 98.6F, BP 100/70 mm of Hg, Pulse 72 bpm, RR 18 breath /minutes and Spo₂96%.

Patient's condition at the time of handing over:

After implementing the immediate care and continuously monitoring the

patients, the EMT observed a slight improvement in the patients' condition. The EMT ensured that the patients were secured in the ambulance and given emergency care according to that. EMT prepared for a smooth hand over to the hospital staff upon arrival and handed over to the Govt. Taluk Hospital Feroke.

Reflection of the patient or patient relative:

The patients' friends and family expressed gratitude for the EMT's prompt response and effective first aid. They appreciated EMTs and Pilot professionalism, good action to the emergency and the reassurance provided during a distressing situation. Bystanders acknowledged the situation, current status and the importance of the swift actions taken by the EMT and Pilot, which contributed to the positive outcome and alleviated their concerns during the ambulance journey.



REFLECTION BY EMT : NIKHIL RAJ K R

"It was a really challenging case, and we took extra care while handling this particular patient. We gave all the possible pre-hospital care to save his life. I feel really proud that our timely intervention saved the life of the patient."

REFLECTION BY PILOT : RAHUL M P

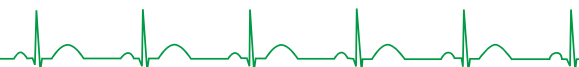"We took the patient from the scene to the hospital without causing any delay, giving maximum care possible. Thanking EMRI GHS for giving me the opportunity to save the lives of others".



CASE DETAILS

AMBULANCE LOCATION : FEROKE THQH
 CASE ID : 20251000014336
 DATE : 05/10/2025
 CALL TIME : 07:38 HRS
 ERCP : Dr. ANKHA SAJEEV
 RECEIVING HOSPITAL : GOVT. TALUK HOSPITAL FEROKE

INCIDENT PHOTOGRAPH



OCTOBER 2025

A CASE OF RTA

Details of the incident:

On 23rd October 2025, our Emergency Response Officer received a call from a Good Samaritan requesting an ambulance for a 24-year-old man involved in a Road traffic accident and had a serious injury with pool of blood. Immediately, our Emergency Response Officer assigned the case to the nearby location of Rathnagiri NH ambulance for support. Ambulance crew reached the scene within a few minutes; BSI precautions were followed by both EMT and Pilot.

Diagnosis or condition:

On assessment, the scene was safe, and the victim was conscious and oriented. He had traumatic multiple injuries and open fractures in his entire right leg, which involved the femoral, tibia and fibula bones.

Pre-hospital Management:

The victim was placed in a supine

position. The wound was washed with normal saline, and bleeding was controlled effectively with an intact dressing. Fractured sites were secured with splinting. After stabilization of the victim's circulation, he was loaded into the ambulance with proper spinal protection through a spine board.

Vital parameters were checked and recorded. HR- 69 bts/min, RR-18 breath/min, BP-90/60 mm Hg, Temp- 98.6° F and SPO2 -96 %. IV line was secured with an 18 G cannula, and Oxygen administered. Past and present required history was collected from the attender. Since the patient complained of severe pain and had hypotension with multiple injuries, ERCP advice was taken. As per the ERCP advice, the victim was administered IV Fluid Normal saline along with the medicine of Inj. Paracetamol. En route to the hospital,

the vitals were checked and recorded. The victim was continuously monitored and reassured. He was safely shifted to the Government Medical College & Hospital, Vellore.

Patient's condition at the time of handover:

During handover, the victim was alert, vital parameters were checked and recorded. HR- 70 bts/min, RR-18 breath/min, BP-110/70 mm Hg, Temp- 97.4° F and SPO2 -98%. The victim was safely admitted to the hospital with stable vital signs, and proper documentation has been done. After 48 hours of follow-up, the victim was under postoperative management.

Reflection of the Patient's relative:

The victim's relative thanked our associates for the excellent care provided by our associates.



REFLECTION BY EMT : DHASARATHAN

"It was a case; the victim had multiple injuries with severe bleeding. Our prompt action helps to revert victim from the dangerous situation."

REFLECTION BY PILOT : WATSON

"I understood the emergency condition, and we were actively involved to save him from the danger."



CASE DETAILS

PATIENT RECEIVING PRE-HOSPITAL CARE IN 108 AMBULANCES

AMBULANCE LOCATION : RATHNAGIRI NH
 CASE ID : 304697
 DATE : 23/10/2025
 CALL TIME : 13:07 HRS
 ERCP : Dr. ANBU
 RECEIVING HOSPITAL : GOVERNMENT MEDICAL COLLEGE & HOSPITAL, VELLORE



A CASE OF TRAIN ACCIDENT

OCTOBER 2025

Details of the incident:

On October 16th, a 33-year-old man named Avinash was at Secunderabad Railway Station. He boarded a train to travel from Secunderabad to Ballarsha. As the train was extremely crowded and there was no space to go inside, he stood near the door on the footboard and continued his journey.

As the train crossed Jangaon station and was approaching Ghanpur station, he suddenly lost his grip and fell down from the footboard. Since he fell from a moving train, the passengers pulled the chain and tried to stop the train, but it eventually stopped only at Ghanpur station. After that, the passengers informed the 108-emergency service and reported the need for help.

Diagnosis or Condition:

The 108 EMT and pilot, upon receiving the information, immediately set out and reached the incident spot. At that time, it was around 3 a.m. Since it was

extremely dark, they walked about two kilometres searching for where the victim had fallen. Finally, they noticed the victim lying there with severe injuries. As he had injuries to his head and hands, they immediately applied bandages to stop the bleeding, placed a C-collar around his neck, and lifted him onto a scoop stretcher. Carrying him along the railway track, they walked back another two kilometres and then shifted him into the ambulance. As soon as the victim was taken into the ambulance, they immediately started administering oxygen to him. Noticing that he was not fully conscious, they promptly departed in the ambulance towards the hospital.

Pre-Hospital Care or Management:

While administering oxygen to the victim, the team continuously monitored all his vital signs: BP 100/70 mm Hg, pulse 110 bpm, respiratory rate 12

bpm, and SpO₂ 90%. The victim was also found to have an altered mental status. All these vital details were communicated over the phone to the ERCP doctor, and further instructions were given. As per the doctor's advice, oxygen therapy was continued, and IV fluids (Ringer's Lactate) were connected. Carefully monitoring the condition of his airway, they transported him with great caution and admitted him to MGM Hospital.

Reflection of the Railway police and Public:

In the pitch darkness, it was very difficult to locate where the victim had slipped and fallen from the moving train. However, they finally managed to find him and safely shift him to the hospital. For this effort, the railway police greatly appreciated and congratulated us, praising how useful and effective the 108 emergency services are.



REFLECTION BY EMT : G RAJENDER

"On Incident Day, the weather conditions were not so good (very cold with a lot of fog), and we did not know where the victim had fallen. In search of the victim, I and the Pilot, walked nearly two kilometres by carrying a torchlight. When we finally found the victim, we felt a great sense of relief. In the determination to save his life, walking those two kilometres did not feel difficult to us at all. Instead, I felt happy and satisfied that we were able to save his life."

REFLECTION BY PILOT : K RAJANNA

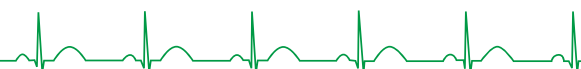"We felt very happy to have been part of the effort to save the life of a person who fell from a moving train. When we had this information from the railway police that the victim had fully recovered and returned home safely, it gave us immense happiness and satisfaction. I realized that no matter how crowded it is, travelling on the footboard is extremely dangerous."



CASE DETAILS

AMBULANCE LOCATION : STATION GHANPUR
 CASE ID : 36120956
 DATE : 16/10/2025
 CALL TIME : 03:04 HRS
 ERCP : Dr. JAGADEESH
 RECEIVING HOSPITAL : MGM HOSPITAL WARANGAL.

MEDIA CLIPPINGS



Details of the incident:

On 18th Oct' 26, Saturday morning, approximately 08:21 Hrs, Ms. Sadhna, aged 14/F, D/O Mr. Ramkhelawan, Mrs. Kajal aged 27/F, Mr. Rohit 20 aged 20/M, Mrs. Prema aged 38/F, resident of Village- Ekasana, Police Station- Bhadokhar, District- Raebareli, Uttar Pradesh, on Saturday morning, Ms. Sadhana was preparing tea for her family at home, it was leakage in LPG cylinder & suddenly blast and all of them got serious burn injuries on different parts of body. Among them, the girl Ms Sadhana was seriously burned, and she became unconscious immediately after the burn injury, and others had serious burn injuries. Theirs neighbor informed the 108 ambulance services about the accident. In response, our Emergency Response Officer promptly dispatched the case to the Civil Line police chawki, DH Raebareli, location for immediate intervention.

Patient Assessment:

Upon arriving at the scene, the EMT followed Body Substance Isolation (BSI) precautions. Pilot Vinesh and EMT Manoj promptly initiated a primary assessment. The patient, Ms Sadhana, was found in critical condition with multiple injuries on the face and over the body, including both hands and both feet of the body, approximately. 36 per cent of burns, and she was found in an unconscious condition, and others were Mrs Kajal, with minor burns over the

body and foot & hand involved approximately. 30 per cent, Mrs Prema, minor burns over the body, including the hand, approx. 28 per cent and 4th one, who is Mr Rohit, both hands, including minor burns over the body, approximately. 18 per cent, all of them having severe pain. EMT Manoj is dressing all burn areas of them precautions with blisters and intact skin. After stabilization, the patients were rapidly transported to the District Hospital Raebareli for further care.

Pre-hospital management:

The 108 Ambulance promptly arrived at the scene, where standard emergency medical protocols were initiated with a rapid primary survey and initial assessment. The primary patient, Ms Sadhana, was found unconscious and in critical condition, while other victims were conscious but in severe pain. Ms Sadhana was carefully extricated and safely secured inside the ambulance, with appropriate blister precautions observed to prevent further tissue damage. Baseline vital parameters were recorded as follows: Pulse – 112 bpm, Respiratory Rate – 28 breaths per minute, Blood Pressure – 138/97 mmHg, Temperature – 105.3°F, and SpO₂ – 89% on room air. On examination, the skin showed multiple blisters and extensive burn injuries. The other patients were experiencing intense pain and appeared lethargic. Following teleconsultation from Dr

Rastogi, the EMT administered Oxygen at a flow rate of 4 litres/minute as advised. Additional critical care measures were carried out, including burn dressing with Silverex ointment, burns spray for pain relief, and covering the patient with a sterile blanket to minimize heat loss and infection risk, as per further guidance from Dr. Rastogi. The patients were stabilized during transportation and subsequently handed over to DH Raebareli for further evaluation and management. The timely pre-hospital care and coordinated efforts of the EMT and ERCP played a crucial role in saving the patient's life

Patient condition at the time of handing over:

Upon arrival at the hospital, the patient's condition of Ms Sadhana was improved; she became stimulated to verbal during on way to DH Hospital Raebareli, and others had improved as pain palliate, as evidenced by stabilized vital signs.

Reflection of the patient or patient's relative:

The patient was safely taken to DH Raebareli. The patient's family expressed deep appreciation for both the EMT and the Pilot, the swift response and efficient handling of the critical situation. It arrived on time and took the patient to the hospital on time, saving their life. We thank the ambulance staff and the government.



REFLECTION BY EMT : MANOJ KUMAR VISHWAKARMA

"It was a good Feeling to save somebody's life. Thanks to our organization from the bottom of my heart, which gave me this golden opportunity to serve. Also, I express special gratitude to my Pilot Mr Vinesh, who supported me a lot in this life-saving mission."

REFLECTION BY PILOT : VINESH

"In this case, I collaborated with EMT Mr Manoj Kumar Vishwakarma to provide proper care. I thank everyone who gave me this opportunity to participate in this noble work of saving lives and serving people. This experience gives me immense satisfaction and a sense of pride."



CASE DETAILS

PATIENT RECEIVING PRE-HOSPITAL CARE IN 108 AMBULANCES & MEDIA CLIPPING

AMBULANCE LOCATION : CIVIL LINE POLICE CHAWKI DH
 RAEBARELI
 CASE ID : 553461
 DATE : 18/10/2025
 CALL TIME : 08:21 HRS
 ERCP : Dr. RASTOGI
 RECEIVING HOSPITAL : DH RAEBARELI DISTRICT-
 RAEBARELI



NOVEMBER 2025

NOVEMBER 2025

A CASE OF BURNS

Details of the incident

On 8th November 2025, a Good Samaritan called our Emergency Response Centre and requested an ambulance for 40 a 40-year-old male who had set fire to himself by pouring petrol over his body under the influence of alcohol. Immediately, our Emergency Response Officer assigned the case to the Pappireddipatti location ambulance for support. The EMT has given pre-arrival instructions to the patient's attendant and reached the scene within a few minutes, where proper BSI precautions were followed under aseptic techniques.

Diagnosis or condition

EMT assessed the level of consciousness, and he was conscious and oriented. During initial assessment, the victim got 80% burns all over the surface of the body in the regions of head, face, chest, abdomen and upper extremities, and

breathing difficulty was present.

Pre-hospital Management

On reaching the scene, the EMT actively involved to remove the burnt clothes. Baseline vital parameters were checked and recorded as HR-118b/min, RR-24 br/min, BP-100/60 mmHg, normal Pupils, RBS-140 mg/dl, SPO2-86% and Temp-98.6F. The victim was loaded into the ambulance, and triage was done, marked as critical. Burnt areas were covered with dry sterile sheets. High-flow oxygen was administered. IV cannulation was done, and fluid, Normal Saline and Ringer's Lactate solution 500 ml was resuscitated as per ERCP advice. Vital parameters were rechecked and noted as unstable. The victim was continuously monitored for further life-threatening conditions and admitted to the Government Medical College Hospital, Dharmapuri.

Patient's condition at the time of handover

At the time of handover, the EMT checked his level of consciousness and found as alert, vital parameters were reassessed and noted as unstable, it is observed that the patient's condition remains same as at the scene. During handover, he was safely handed over to the hospital. After stabilization with fluid and airway management, the case was referred to a higher centre for advanced treatment. On 48 hours of follow-up, the patient was under the Burns Intensive Care Unit.

Reflection of the Patient's relative

Patient's spouse thanked our EMT & pilot for the specialised care provided to him on time in order to save his precious life and also, she appreciated them for their dedication and kindness.

**REFLECTION BY EMT : BAYASH**

"It was a case, the patient's condition was very critical at the scene, I provided good pre-hospital care, and also my pilot was actively involved and supported well in shifting and transporting to the hospital."

REFLECTION BY PILOT : GOVINDHAN

"I understood the patient's critical condition, and during that time my concentration was fully on reversing the patient from the danger."

**CASE DETAILS****PATIENT RECEIVING PRE-HOSPITAL CARE IN 108 AMBULANCES**

AMBULANCE LOCATION : PAPPIREDDIPATTI GH
 CASE ID : 105211
 DATE : 08/11/2025
 CALL TIME : 08:10 HRS
 ERCP : Dr. BALU
 RECEIVING HOSPITAL : GOVERNMENT MEDICAL
 COLLEGE HOSPITAL, DHARMAPURI



A CASE OF MEDICAL EMERGENCY

NOVEMBER 2025

Details of the incident:

On 28th Nov 2025 at 9:17 Hrs, our emergency response center received a call from Kazardya, Balli, stating that there was a lying case on the floor. Cuncolim ambulance was the nearest available ambulance. After taking scene details, the EMT and Pilot rushed to the scene with the relevant equipment to provide necessary Pre-hospital care. En route towards the scene, EMT advised the caller to control any external bleeding of the patient with direct pressure and not to feed him anything orally. Ensuring scene safety and maintaining BSI precautions, our team arrived on the scene.

Diagnosis or condition:

After assessing scene safety, the

EMT and the Pilot approached the patient. On arrival at the scene, the patient was found unconscious. EMT quickly checked the ABC of the patient. The patient was a 40-year-old male and had a history of Diabetes and alcohol intake. RBSL was checked without wasting time, which was found to be 15 mg/dl. EMT called ERCP and explained the condition of the patient. ERCP advised to access IV cannula, IV dextrose, Inj. Ondem, Inj. Rantac and a vitals monitor.

Pre-hospital management:

EMT gave all the advised prehospital care to the patient as per ERCP. The patient was shifted in the ambulance on a spine board, and vitals were recorded. Initial assessment revealed vital signs as

follows: BP 110/60mm Hg, Pulse 116 bpm, Respiratory Rate 26 breaths/min, SpO₂ 96%.

Patient condition at the time of handover:

After implementing the necessary interventions and continuously monitoring the patient, EMT observed an improvement in the patient's condition. RBSL was increased to 210 mg/dl. The EMT gave reassurance to the patient. Meanwhile, the ambulance reached the destination hospital. Patient was handed over in the casualty of PHC Balli.

Reflection of the patient:

Thank you to the ambulance team for saving my life!



REFLECTION BY EMT : MAHENDRA MAURYA

“Before reaching the Scene, as per the information of bystanders about the victim's position, we thought that the victim was unstable. As it was our duty to save his life, we assessed him and identified the problem (Hypoglycemia) and provided proper care and other skill sets as per protocols. After reaching the Hospital, we saw our pre-hospital care team, and they appreciated us a lot, for which we are very proud.”


REFLECTION BY PILOT: MANOHAR VELIP

“Victim family members and the Hospital staff appreciated our services for good pre-hospital care, praising our sincere efforts in helping the victim in a serious condition”



CASE DETAILS

AMBULANCE LOCATION : CUNCOLIM PHC, SOUTH GOA
 CASE ID : 20251100022779
 DATE : 28/11/2025
 CALL TIME : 09:17 HRS
 ERCP : Dr. RAJAT
 RECEIVING HOSPITAL : PHC BALLI



NOVEMBER 2025

A CASE OF COMPLICATION IN PREGANCY

Details of the incident:

On 23rd November 2025, an ordinary afternoon at CHC Kalol turned into a race against time. At 13:43 hrs., a distress call was received from CHC Halol. A 19-year-old primigravida, Urvashiben Patel, was experiencing repeated convulsions at home. With her pregnancy at full term and her condition rapidly deteriorating, every minute mattered. Without delay, the 108 ambulance was dispatched. Guided by pre-arrival instructions, EMT Mehul Kumar Baria and Pilot Prafulkumar Parmar moved swiftly, aware that they were not just responding to an emergency, but carrying the hopes of an entire family.

Diagnosis or condition:

Upon reaching the patient, the team encountered a deeply alarming scene. The young mother lay unconscious, struggling for breath, with oral secretions, severe hypertension, rapid breathing, and falling oxygen levels - clear signs of eclampsia, a life-threatening obstetric emergency.

Pre-hospital management:

With calm precision, EMT Mehul Kumar

immediately took charge. The airway was cleared, a nasopharyngeal airway was secured, and bag-valve-mask ventilation with high-flow oxygen was initiated. Working seamlessly, the EMT and Pilot safely transferred the patient into the ambulance, transforming it into a moving critical care unit. As the ambulance sped towards definitive care, the situation remained volatile. The patient suffered two more convulsive episodes en route, testing the team's skill and composure. Despite the challenges, ventilation was maintained, vital signs were closely monitored, and online medical guidance was sought without hesitation. In coordination with ERCP Dr. Shalu Patel, the EMT administered Magnesium Sulphate intravenously, a decisive intervention crucial for controlling eclamptic seizures. Oxygenation and positioning were meticulously maintained, ensuring stability through every kilometre of the journey.

Patient condition at the time of handing over:

After covering approximately 42

kilometers, the ambulance reached SSG Hospital, Vadodara. Thanks to timely interventions, continuous monitoring, and unwavering focus, the patient's condition had significantly improved by the time of handover.

For the anxious family, the sight of their loved one stable and alive was nothing short of a miracle.

Reflection of the patient or patient's relative:

The patient's relatives expressed heartfelt appreciation for the dedication, professionalism, and compassionate care provided by the 108 team. In their moment of greatest fear, the EMT and Pilot stood as pillars of hope.

Because Every Second Counts:

This life-saving mission from Panchmahal district stands as a powerful reminder of what 108 Emergency Services represents - speed, skill, teamwork, and compassion. When preparation meets purpose, lives are saved, futures are protected, and hope is restored.

**REFLECTION BY EMT : MEHULKUMAR BARIA**

"I feel extremely honoured to be recognized as a Saviour for the first time. While awards are always encouraging, the true reward lies in saving a patient's life and bringing relief and smiles to the patient's family. I sincerely thank God and our organization for entrusting me with this responsibility and giving me the opportunity to serve humanity."

REFLECTION BY PILOT : PRAFULKUMAR PARMAR

"Being selected as a Saviour for the first time is a matter of great pride for me. Contributing to the mission of saving lives is deeply fulfilling, and I feel truly blessed to be part of this service. Effective teamwork and coordination make extraordinary outcomes possible."

**CASE DETAILS****PATIENT RECEIVING PRE-HOSPITAL CARE IN 108 AMBULANCES**

AMBULANCE LOCATION : CHC KALOL
CASE ID : 20251100187647
DATE : 23/11/2025
CALL TIME : 13:43 HRS
ERCP : Dr. SHALU PATEL
RECEIVING HOSPITAL : SSG, VADODARA



A CASE OF RTA

NOVEMBER 2025

Details of the incident:

On 28th November 2025 at 2:05 Hrs., Emergency Response Centre (ERC) received a call from a good Samaritan from the Mundgod road signal of Haveri District, who was very frightened and requested an ambulance urgently. On asking about case details, our Emergency Response Officer (ERO) stated that the victims were approximately 40 years old, and an accident occurred as their car rolled over into a deep dry canal from the road near the Tayavva temple, Mundgod road. The nearest available ambulance was Thadasa cross location, which had just then completed a case and had made a release call (R Call) to ERC stating that they were ready to take next case. The case was immediately assigned to an ambulance with Pilot Mr. Krishnaji and EMT Mr. Arunkumar on duty, and they reached the victim location, which was 5 km's away, within 09 minutes of duration.

Diagnosis or condition:

When the 108-crew reached the scene, EMT found that one of the victims had a right femur bone open fracture and

irregular laceration with severe bleeding & another victim had a head injury associated with lacerations. EMT assessed and found that the victims were semiconscious. Victims were shifted into the ambulance using SMRD and assessed for bleeding and controlled with the direct pressure technique. Baseline vitals were recorded on the way and found to be victim -1 & Pulse: 112 bpm, BP-150/60 mm of Hg, Respirations 19 breaths/minutes, SPO2 98% of victim -2.

Pre-hospital management:

EMT Mr. Arunkumar realized the emergency condition and, after shifting the victims immediately into the ambulance, padded the right leg adequately and splinted it. Meanwhile, he had instructed Pilot Mr Krishnaji to be prepared to shift the victim to a nearby medical facility. EMT applied large pads covered wound, then a long splint was applied to the right leg. Before and after splinting, PMS were checked. At the right lateral of the body, lacerated wounds are treated. IV line was accessed and started fluid RL with 60 drops/minute. Rechecked vitals were

recorded, BP-100/70 mm of Hg, Pulse-126 bpm, RR-16 breaths/min, SPO2-98%, the victim was diaphoretic & agitated. On consultation with ERCP Dr. Harsha, Oxygen was started at 6 lts/min & shifted to the nearest hospital of the Hubli District emergency room for further management.

Patient condition at the time of handing over:

Hospital doctors appreciated EMT & Pilot for their presence of mind and the accurate pre hospital management which was given to the victims on scene & in the ambulance before reaching the hospital. The victims were immediately attended by a Team of Doctors for further evaluation of their condition.

Reflection of the patient or patient relative:

The victim's brother showered blessings and his gratitude towards our ambulance team. The condition of the victims was stable during the 48-hour follow-up call. Victims were shifted to the higher facility centre for further surgical care.



REFLECTION BY EMT : ARUNKUMAR D O

"It was a very challenging case for me, and I felt very much satisfied after shifting the victims to the hospital within the golden hour. It gives tremendous pleasure to serve people when they are in need of our help & support. I am thankful to EMRI GHS for giving me an opportunity to save the life of a needy person."

REFLECTION BY PILOT : KRISHANAJI

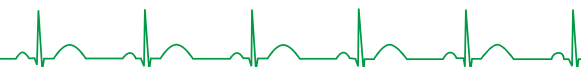"I am happy because I took part in Pre-Hospital Care & I was able to shift the patient on time to the hospital, which made the work of doctors and other staff to treat effectively, and I would like to say thanks to EMRI GHS for giving me an opportunity to work as a Pilot in 108 Ambulance to serve the community."



CASE DETAILS

PATIENT RECEIVING THE PRE HOSPITAL CARE IN 108 AMBULANCES

AMBULANCE LOCATION : THADASA CROSS
 CASE ID : 3058927
 DATE : 28/12/2025
 CALL TIME : 2:05 HRS
 ERCP : Dr. HARSHA
 RECEIVING HOSPITAL : SUCHIRAYU HEALTH CARE HUBLI



NOVEMBER 2025

A CASE OF ASSAULT

Details of the incident:

Kottathara GTH Attapady ambulance was dispatched to respond to a call regarding a sexual assault. The incident occurred in Sholayur-pkd, Attappadi tribal area (terrain area) at 16:06 hrs. The ambulance reached the scene within 33 minutes of receiving the call.

Diagnosis or condition:

The EMT quickly assessed the patient's condition, Smit. Kali, a 38-year-old lady, was covered with blood, and she had lost consciousness. On observation found that the victim was brutally assaulted physically and sexually. Noticed a vaginal laceration approximately 4 cm with severe bleeding.

Pre-hospital management:

The patient was immediately shifted

into the ambulance, and the EMT quickly started to provide pre-hospital care such as an IV line, starting IV fluids 25% dextrose and a 500 ml Normal Saline bolus. Given wound care and an applied pad. Checked the carotid pulse, and it was feeble. monitored the vitals, BP -80/60 mm Hg, pulse - 56 b/m, RBS - 56Mg/dl and SpO2 % saturation was unable to read due to cold extremities.

Patient condition at the time of handing over:

After implementing the necessary interventions and continuously monitoring the patient, the EMT observed slight changes in vitals. The EMT ensured that the patient was secured in the ambulance and given care according to that. EMT prepared for a smooth handover to hospital

staff upon arrival, and the patient is handed over to the Government Tribal Speciality Hospital, Kottathara.

Reflection of the patient or patient relative:

Patient family members expressed gratitude for the EMT's prompt response and effective management in bleeding control measures used and care en route. They appreciated the EMT's professionalism, good action to the emergency, and the reassurance provided during the distressing situation. Family members acknowledged the importance of the swift actions taken by the EMT and Pilot, which contributed to the positive outcome and alleviated their concerns during the ambulance journey.



REFLECTION BY EMT : ABEY ABRAHAM THOMAS

"It was a very challenging and unique unfortunate case, and we took extra care while handling this patient from the tribal terrain area. We provided all possible Pre-Hospital Care to save her life. I feel really proud that our timely intervention helped save the patient's life."

REFLECTION BY PILOT : VIPIN P R

"We took the patient from the scene to the hospital without causing any delay, even though the scene was a terrain area, giving maximum care possible. Thanking EMRI GHS for giving me the opportunity to save the lives of others."



CASE DETAILS

AMBULANCE LOCATION : KOTTATHARA GTH ATTAPADY
 CASE ID : 20251100005658
 DATE : 02/11/2025
 CALL TIME : 16:06 HRS
 ERCP : Dr. ANAKHA SAJEEV
 RECEIVING HOSPITAL : GOVERNMENT TRIBAL SPECIALITY
 HOSPITAL KOTTATHARA

INCIDENT PHOTOGRAPH



A CASE OF ELECTROCUTION

NOVEMBER 2025

Details of Incident:

On 31st October 2025, on the main road from Mahabubnagar to Nagarkurnool, construction work was going on near the Cooperative Bank. During the process of lifting iron rods to lay an upper floor, a worker named Srinu, along with others working with him, raised an iron rod, which accidentally came into contact with an overhead 33 KV electric line. As a result, Srinu and two others suffered electric shock. In this incident, Srinu was seriously injured, while the other two sustained minor injuries. People nearby immediately called 108 for assistance.

Diagnosis or Condition:

After receiving the information, the EMT and the Pilot immediately rushed to the scene. They first checked whether the situation was safe, then examined the three persons at the spot. Observing that the victim named

Srinu was seriously injured, they shifted him into the ambulance using a scoop stretcher. It was assessed that Srinu, the victim who suffered a severe electric shock, had sustained third-degree burn injuries covering about 25 per cent of his body

Pre-Hospital Care or Management:

Immediately after shifting the victim into the ambulance, oxygen was administered at 10 liters per minute. Blood pressure, pulse, respiration, and all other vital signs were checked and recorded (BP: 161/112 mm Hg, Pulse: 102 bpm, R/R: 20 bpm, SpO₂:95%). When the victim complained of severe pain, the EMT contacted the ERCP doctor and explained all the vitals, along with the signs and symptoms. As per the ERCP doctor's advice, an injection of Tramadol was given intramuscularly,

and an IV cannula was inserted to administer IV fluids if required. While carefully monitoring the victim's airway condition, he was then shifted to the hospital.

Reflection of the Family numbers and bystanders:

In this case, my husband, Srinu, suffered a severe electric shock after coming into contact with a 33kV power line, and I feared he had passed away. However, within a few minutes, the 108 ambulances arrived, which gave us immense courage. Thanks to the prompt treatment provided in the ambulance and the quick transfer to the hospital, he is alive today. This was made possible solely because of the dedicated 108 service. We sincerely hope that 108 services continue to operate with the same efficiency, and we will always remain deeply grateful to you.



REFLECTION BY EMT : RAVI KUMAR

"When we heard about the electric shock, we were initially worried about the safety of the scene. However, once we reached there, everything was safe. Seeing the victim severely electrocuted was very distressing, especially since he works daily for his livelihood. But seeing him alive today has brought me immense happiness."

REFLECTION BY PILOT : VENKATAIAH

"I am very happy that I was able to play a part in quickly taking the victim of the electric shock to the hospital and helping save his life. Moreover, when I heard the victim's wife's words, I was filled with deep emotion. I feel fortunate to witness and be part of organizations that save lives like this."



CASE DETAILS

AMBULANCE LOCATION : BIJINEPALLY
 CASE ID : 36230748
 DATE : 31/10/2025
 CALL TIME : 11:54 HRS
 ERCP : Dr. MOUNIKA
 RECEIVING HOSPITAL : GOVERNMENT GENERAL HOSPITAL NAGARKURNOOL.

MEDIA CLIPPING



A CASE OF MEDICAL EMERGENCY

NOVEMBER 2025

Details of the incident:

On Monday evening at approximately 7:45 Hrs., the 108 Emergency Response Center received a call from a family member of Mr. Subhod, a 30-year-old male from Village- Singhpur, Post Manchna, PS. Alau, District Mainpuri, reporting acute onset of left-sided chest pain for 1 hour, and requesting urgent ambulance assistance. In a prompt reply, our Emergency Response Officer dispatched this call to the DH Mainpuri ambulance location for immediate intervention.

Patient Assessment:

Upon arrival at the scene, the Emergency Medical Technician, Mr Kanhaiya Lal, found the patient conscious but visibly distressed, clutching his left chest. The patient complained of severe, sharp left-sided chest pain radiating slightly to the shoulder, and associated shortness of breath. The EMTs offered emotional support and reassurance to both the patient and his family members to help reduce anxiety. The patient was

immediately shifted into the ambulance, and semi follower position was maintained and high-flow oxygen was started. Vitals were checked and recorded.

Pre-hospital management

108 Ambulance immediately arrived at the scene, where standard emergency medical protocols were initiated with a quick primary survey and initial assessment. Ensuring an open airway and administering high-flow oxygen to treat hypoxia, and after that, placing the patient in a semi-Fowler's position to ease respiratory effort, the EMT also gave reassurance to reduce anxiety and prevent further elevation of heart rate. Baseline vital parameters were recorded: pulse 112 bpm, respiratory rate 20 breaths per minute, blood pressure 140/80 mm Hg, temperature 98.5°F, and SpO₂ 98% on oxygen. The patient's cyanosis, cool, clammy skin, and tachycardia indicated potential cardio-respiratory compromise, possibly due to acute coronary syndrome. After vitals & SAMPLE history taken by the EMT's, then he contacted ERCP. In the

teleconsultation, the EMT administered medications as advised: Tab. Sorbitrate for pain relief and cardiac cause, Inj. Rantac for gastritis, additional critical care measures were implemented as per further guidance from Dr Amit. The patient was stabilized during transportation and later handed over to DH Mainpuri for advanced care management.

Patient condition at the time of handing over:

Upon arrival at the DH Mainpuri, the patient's condition had improved, as evidenced by stabilized vital signs.

Reflection of the patient or the patient's relative:

The patient was safely taken to D H Mainpuri. The patient's family expressed deep appreciation for the EMT and the Pilot, the swift response and the efficient handling of the critical situation. It arrived on time and took the patient to the hospital on time, saving their life. We thank the ambulance staff and the government.

**REFLECTION BY EMT : KANHAIYA LAL**

"At the scene, the victims were in critical condition with severe pain and associated respiratory problems. I have provided pre-hospital care with guidance from the ERCP and EMLC department, who trained me to provide excellent care. I feel very blessed for being an Emergency Medical Technician in saving lives. Also, I express special gratitude to my pilot, Mr Bablesh, who supported me a lot in this life-saving mission."

REFLECTION BY PILOT : BABLESH

"In this case, I collaborated with EMT Mr Kanhaiya Lal to provide proper care. I thank everyone who gave me this opportunity to participate in this noble work of saving lives and serving people. This experience gives me immense satisfaction and a sense of pride."

**CASE DETAILS****PATIENT RECEIVING PRE-HOSPITAL CARE IN 108 AMBULANCES**

AMBULANCE LOCATION : DH-MAINPURI
 CASE ID : 95708
 DATE : 06/11/2025
 CALL TIME : 19:53 HRS
 ERCP : Dr. AMIT
 RECEIVING HOSPITAL : DH MAINPURI
 DISTRICT- MAINPURI



DECEMBER - 2025

A CASE OF WORK PLACE ACCIDENT

DECEMBER 2025

Details of the incident:

On 09th December 2025, a 26-year-old male, Shaik Moulana, arrived at his workplace as usual to perform stone-cutting work. During the course of his work, the stone-cutting blade suddenly broke and struck him on the forehead. This resulted in profuse bleeding. Due to the severity of the bleeding, the people present at the site became frightened and were unable to approach the victim. Recognizing the seriousness of the situation, they immediately contacted the 108-emergency service for urgent medical assistance.

Diagnosis or Condition:

Upon receiving the information, the 108 medical staff promptly reached the incident location with full preparedness. The injured person was carefully assessed. On examination, it was found that the broken blade was embedded in the frontal (forehead) region of the victim. The team identified that attempting to remove the blade could lead to increased bleeding

and further complications. Therefore, the blade was carefully stabilized using sterile gauze pads and gauze rolls without disturbing the wound, and effective measures were taken to control the bleeding. After initial stabilization, the victim was cautiously shifted into the ambulance. As the bleeding was excessive and the injury was serious, the patient was immediately transported to the nearest hospital for further evaluation and definitive management.

Pre-Hospital Care or Management:

Immediately after shifting the victim into the ambulance, oxygen was administered at 10 litres per minute. Subsequently, a complete assessment of the victim's vital signs was carried out. The vitals were recorded as follows: blood pressure 90/50 mm Hg, pulse rate 56 beats per minute, respiratory rate 26 breaths per minute, and SpO₂ 86%. The victim was responsive only to painful stimuli. Considering the critical condition, the EMT

contacted the ERCP doctor over the phone and explained the victim's condition and vital parameters. As per the advice of Dr Srikanth, intravenous fluids (Ringer's Lactate) were initiated, and the victim was placed in the shock position. Airway management was continuously maintained, and the patient was carefully transported to Gandhi Hospital for further advanced care.

Reflection of the Family numbers and bystanders:

Truly, the 108 staff are very courageous. When the stone cutting blade pierced the victim's forehead, we were extremely frightened and unable to go near him. However, the 108-team arrived immediately, controlled the bleeding, provided very critical treatment inside the ambulance, and promptly shifted him to the hospital. Indeed, 108 services are unforgettable and invaluable. We bow our heads and express our sincere gratitude to the entire 108 team.



REFLECTION BY EMT : CHITRAM RAVI

"Along with Pilot Mr J Prabhakar, who arrived at the scene and saw the victim, we felt momentarily frightened, as a blade was embedded in his forehead and his face was covered in blood, making the situation appear extremely critical. Despite this, we remained calm and carefully managed the case, ensuring safe handling and timely transport to the hospital. The victim is now stable and safe. Being part of the effort that helped save a person's life has given me immense satisfaction and a deep sense of fulfilment."

REFLECTION BY PILOT : PRABHAKAR

"I have never handled a case like this before in my service life. However, this case gave us new courage and happiness. I feel very glad and proud that I was able to be involved in managing this case along with the EMT by proper Pre-Hospital Care protocols."



CASE DETAILS

PATIENT RECEIVING PRE-HOSPITAL CARE IN 108 AMBULANCE & MEDIA CLIPPING

AMBULANCE LOCATION : BIJINEPALLY
 CASE ID : 36057478
 DATE : 09/12/2025
 CALL TIME : 18:43 HRS
 ERCP : Dr. SRIKANTH
 RECEIVING HOSPITAL : GANDHI HOSPITAL HYDERABAD.



A CASE OF MEDICAL EMERGENCY

DECEMBER 2025

Details of the incident:

The 108 Emergency Ambulance Service plays a crucial role in providing timely, life-saving pre-hospital care. Neurological emergencies such as epilepsy require prompt assessment, airway protection, and rapid transport to prevent complications. This case highlights the effective management of a patient with an epileptic seizure by the 108-ambulance team, demonstrating professionalism, clinical skills, and dedication to patient safety. On 08th December 2025 at 20:39 Hrs., our emergency response centre received a call from Betoda, stating that there was a medical case of seizures with multiple episodes. After taking scene details, the EMT and Pilot rushed to the scene with the relevant equipment to provide necessary Pre-Hospital Care.

En route towards the scene, EMT advised the caller not to feed him anything orally. Ensuring scene safety and maintaining BSI precautions, our team arrived on the scene.

Diagnosis or condition:

After assessing scene safety, the EMT and pilot approached the patient. On arrival at the scene, the patient was found semi-conscious and disoriented. The patient was a 45-year-old male and was found to be responding only during pain stimulation. The patient had secretions in the mouth with respiratory distress. Immediately, the patient was shifted into the ambulance.

Pre-hospital management:

Without wasting time, EMT recorded vitals. Initial assessment revealed vital signs: BP 100/70 mm Hg, Pulse 112

bpm, Respiratory Rate 20 breaths/min, SpO₂ 92%. EMT called ERCP. Dr. Navjyot was on duty and advised IV Access, oxygen, Position, Inj. Midazolam, suctioning, and vitals monitor. EMT gave all the advised prehospital care to the patient as per ERCP.

Patient condition at the time of handover:

After implementing the necessary interventions and continuously monitoring the patient, the EMT observed an improvement in the patient's condition. The EMT gave reassurance to the patient. Meanwhile, the ambulance reached the destination hospital. Patient was handed over in the casualty of SDH Ponda.

Reflection of the patient:

Thank you to the ambulance team.



REFLECTION BY EMT : PRARTHANA PANDURANG KOLAMKAR

"We have followed all the Pre-Hospital Care protocols of medical emergency and carefully handled the case. It was a great satisfaction to my co-worker and me to provide good pre-hospital care to the victim, who was suffering from status epilepsy is a critical condition. On the telephone, the victim's family members called our ambulance staff and expressed their gratitude and appreciation for providing the good, timely services."

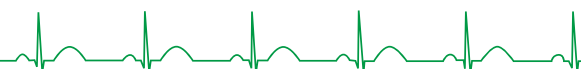
REFLECTION BY PILOT : DATTARAM R DESSAI

"Later, on the telephone, the victim's family members called our ambulance staff and expressed their gratitude and appreciation for providing the good, timely services."



CASE DETAILS

AMBULANCE LOCATION : USGAO PHC, SOUTH GOA
 CASE ID : 20251200006675
 DATE : 08/12/2025
 CALL TIME : 20:39 HRS
 ERCP : Dr. NAVJYOT
 RECEIVING HOSPITAL : SDH PONDA



Details of the incident:

Early on 26th November, 2025, every second counted. At 02:44 hrs., a 108 Emergency Ambulance was dispatched for a high-stakes mission: an IFT case involving the transfer of a primigravida mother in imminent preterm labor with twins from CHC Maliya to an appropriately equipped specialised facility. Manned by EMT Alpeshkumar Bhidol and Pilot Shahrukh Shekh, the team responded with precision and urgency. From the moment of deployment, their focus remained solely on the safety of the mother and her newborns, demonstrating the excellence and readiness of our 108 Ambulance team.

Diagnosis or condition:

After reaching the scene and completing the initial assessment, the case was identified as a high-risk obstetric emergency. The mother was experiencing severe labor pain with imminent delivery, warranting urgency. EMT promptly coordinated with ERCP Dr Rushi for inter-facility transfer. With assistance from the Pilot and the patient's relatives, the mother was safely transferred into the ambulance, ensuring proper positioning and safe transport to the referral facility.

Pre-hospital management:

During transit, the clinical situation escalated rapidly, culminating in on-road twin delivery, markedly increasing maternal and neonatal risk. Demonstrating exceptional composure and clinical proficiency, the EMT promptly conducted the deliveries within the confined ambulance setting. The first twin was delivered in vertex presentation with spontaneous cry and was provided routine newborn care. The second twin was delivered in vertex presentation with an intact amniotic sac and presented with severe neonatal depression, characterized by absence of cry, absent heart rate as well as respiratory effort, and an APGAR score of 0 at birth, consistent with severe birth asphyxia. Recognizing the critical condition, the EMT immediately initiated advanced neonatal resuscitation, including airway positioning, suctioning, and prolonged cardiopulmonary resuscitation as per NRP protocol, while maintaining continuous communication with ERCP Dr Rushi and Dr Patel. In coordination with ERCPs, the EMT administered Inj. Oxytocin and IV RL 500 ml to the mother, and continued Neonatal Resuscitation to the second baby. Through skilled pre-hospital intervention, sustained resuscitative efforts,

and unwavering dedication, the EMT played a decisive role in restoring vital signs and ensuring neonatal stabilization prior to hospital arrival.

Patient condition at the time of handing over:

After covering approximately 60 kilometers, the ambulance reached Civil Hospital, Junagadh. Owing to timely pre-hospital interventions, continuous monitoring, and focused neonatal resuscitation, the patient's condition had significantly stabilized at the time of handover. For the anxious family, witnessing their loved ones to be stable and alive was a profound moment of relief and reassurance.

Reflection of the patient or the patient's relative:

The patient's relatives conveyed heartfelt appreciation for the dedication, professionalism, and compassionate care demonstrated by the 108 Emergency Services team. In a moment marked by fear and uncertainty, the EMT and Pilot emerged as steadfast pillars of support, transforming a critical emergency into a story of survival and hope.



REFLECTION BY EMT : ALPESHKUMAR BHIDOL

"Honoured to be named a 'Saviour'! By putting my training into action, I assisted in a preterm delivery and provided critical NNR support, saving a mother and her two newborns. I am deeply grateful to 108 GVK EMRI for the chance to serve, and to my incredible team-Pilot & Emergency Response Center Physicians-for their vital support in this life-saving mission."

REFLECTION BY PILOT : SHAHRUKH SHEKH

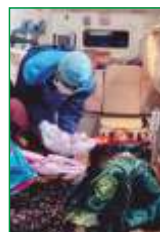"I am deeply honoured that our mission has been recognized as the 'Saviour of the Month.' Working alongside EMT Alpeshkumar Bhidol, I supported a critical delivery and provided essential Neonatal Resuscitation (NNR). I am grateful for this opportunity to serve my community and save lives; there is no greater satisfaction than seeing a patient recover."



CASE DETAILS

PATIENT RECEIVING PRE-HOSPITAL CARE IN 108 AMBULANCE AND MEDIA CLIPPING

AMBULANCE LOCATION : MALIYAHATINA
 CASE ID : 20251100209916
 DATE : 26/11/2025
 CALL TIME : 02:44 HRS
 ERCP : Dr. RUSHI AND Dr. PATEL
 RECEIVING HOSPITAL : CIVIL HOSPITAL, JUNAGADH



A CASE OF RTA

DECEMBER 2025

Details of the incident:

On 25th December 2025 at 05:47 hrs., Emergency Response Center (ERC) received a call from a good Samaritan from Tumkuru District and requested an ambulance urgently. On asking about case details, our Emergency Response Officer (ERO) stated that the victims were a daily wage worker, approximately 35 years old, and an accident occurred between a two-wheeler and a truck near Nandi halli main road. The nearest available ambulance was the Kyathsandra PHC location, which had completed a case and had made a release call (R Call) to ERC stating that they were ready to take the next case. The case was immediately assigned to an ambulance with Pilot Mr Sangamesh and EMT Ms. Sowbaghya on duty, and they reached the victim location, which was 15 km away, within 22 minutes of duration.

Diagnosis or condition:

When the 108-crew reached the scene, EMT found that one of the victims had both legs injured with a bone open fracture and

irregular laceration with severe bleeding. EMT assessed and found that the victims were semiconscious & under the influence of alcohol, non-cooperative, and exhibited aggressive behaviour. The victim was shifted into the ambulance using SMRD and assessed for bleeding and controlled with the direct pressure technique. No visible injury was found on the head.

Pre-hospital management:

EMT Ms Sowbaghya realized the emergency condition and after shifting the victim immediately into the ambulance with the right leg padded adequately and splinted. Meanwhile, she had instructed Pilot to be prepared to shift the victim to a nearby medical facility. EMT applied large pads to the covered wound then long splint applied to the right leg. Before and after splinting, PMS were checked. At the right lateral of the body, lacerated wounds are treated & suspecting internal head injury, a C-collar is applied. IV line was accessed and started fluid RL at 60/drops/minute. Vitals were recorded,

BP-100/70 mm of Hg, Pulse-126 bpm, RR-16 breaths/min, SPO2-98%, the victim was diaphoretic & agitated. On consultation with ERCP, Dr Harsha Oxygen was started at 6 lts/min & shifted to the nearest hospital of Tumkuru District hospital emergency room, for further management.

Patient condition at the time of handing over:

Hospital doctors appreciated EMT & Pilot for their presence of mind and the accurate pre-hospital management which was given to the victims on scene & in the ambulance before reaching to the hospital.

Reflection of the patient or patient relative:

The victim's family showered blessings and gratitude towards our ambulance team. The condition of the victim was stable during the 48-hour follow-up call. Victims were shifted to the higher facility centre for further surgical care.



REFLECTION BY EMT : SOWBAGHYA

"It was a very challenging case for me to deal with a drunken & aggressive behaving victim, and I felt very much satisfied after shifting the victim to the hospital within the golden hour. It gives tremendous pleasure to serve people when they are in need of our help & support. I am thankful to EMRI GHS for giving me an opportunity to save the life of a needy person."

REFLECTION BY PILOT : SANGAMESH

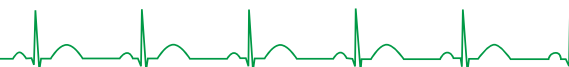"I am happy because I took part in Pre-Hospital Care & I was able to shift the patient on time to the hospital, which made the work of doctors and other staff to treat effectively, and I would like to say thanks to EMRI GHS for giving me an opportunity to work as a Pilot in 108 Ambulance to serve the community."



CASE DETAILS

AMBULANCE LOCATION : KYATHSANDRA PHC
 CASE ID : 3143638
 DATE : 25/12/2025
 CALL TIME : 05:47 HRS
 ERCP : Dr. HARSHA
 RECEIVING HOSPITAL : TUMAKURU DH

INCIDENT PHOTOGRAPHS



Details of the incident

On 20th December, 2025, a 75-year-old woman was accidentally hit by the bus near Villupuram Bus Stand. A Good Samaritan witnessed the vehicular crash and promptly activated our Emergency Response Centre, and stated about the incident and the condition of the victim. Immediately, our Emergency Response Officer assigned the case to the Kandamangalam location ambulance for instant support.

Diagnosis or condition

Upon arrival, the EMT assessed the level of consciousness of the victim and found that the victim was conscious and oriented. She had a complaint of sustained serious injury in the left side of below knee with major bleeding, giddiness and multiple abrasions present in various

regions of the body. The victim was placed in a Supine position, vital Parameters were checked and recorded as HR-104 bt/min, RR-14 br/min, BP-110/60 mm Hg, Temp-98.6 F, Pupils reacting normal to light and SPO2-99%. Splinting was done, and immobilization was achieved, and the injured sites were stabilized, wound care given, and the open wound was dressed properly. The victim was loaded into the ambulance using a stretcher and triaged as a very urgent category. IV cannula inserted. ERCP advice taken and IV fluids were administered as per ERCP advice. Vital parameters were checked and recorded every 5 minutes once. The victim was reassessed for any potential complications that arose, and she was safely transported to Government Medical College Hospital, Villupuram.

Patient's condition at the time of handover

At the time of handover, the EMT checked her level of consciousness and found her to be conscious and oriented. Vital parameters were reassessed and noted as HR-110 bts/min, RR-14 br/min, BP-110/70 mm Hg, Temp-98.6 F, Pupils reacting normally to light and SPO2- 98%. It is observed as no significant changes in the victim's condition, and she was safely handed over to the hospital with proper documentation.

Reflection of the Patient's relative

The victim's son expressed gratitude towards the 108 Ambulance services for their prompt response and excellent pre-hospital care, which helped save his mother's life.



REFLECTION BY EMT : VIJAYARAJ

"It was a serious case; the victim had severe injury and was screaming with pain on arrival. We understood her critical situation and provided good pre-hospital care to save her life. ERCP coordinated well to manage this case effectively, and my Pilot assisted in a proper way to save the victim."

REFLECTION BY PILOT : THIRUMALPATHI

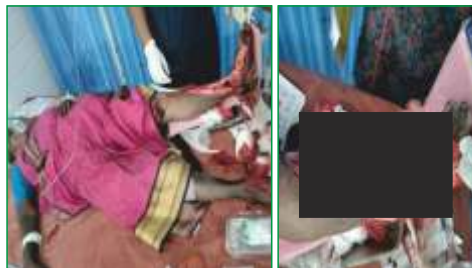"Our great effort with confidence helps to save the victim's life with good care and support."



CASE DETAILS

PATIENT RECEIVING PRE-HOSPITAL CARE IN 108 AMBULANCES

AMBULANCE LOCATION : KANDAMANGALAM PHC
 CASE ID : 248975
 DATE : 20/12/2025
 CALL TIME : 15:45 HRS
 ERCP : Dr. BALU
 RECEIVING HOSPITAL : GOVERNMENT MEDICAL COLLEGE HOSPITAL, VILLUPURAM



A CASE OF RTA - MCI

DECEMBER 2025

Details of the incident:

On Tuesday evening, approximately 17:12 PM, at the Maigalganj crossroads, In the accident, Mr. Kuldeep, a resident of Hasanpur village, along with his son Mst. Satyam's wife, Mrs Mahima, and another girl were travelling somewhere on the motorcycle. When they reached the Maigalganj crossroads, a speeding DCM truck hit their bike, and the bike rider, the couple and two other members of the same family were injured. A Good Samaritan informed the 108 ambulance services about the accident. In response, our Emergency Response Officer promptly dispatched the case to the CHC Maigalganj, District-Lakhimpur Kheri location for immediate intervention.

Patient Assessment:

Upon arriving at the scene, the EMT followed Body Substance Isolation (BSI) precautions. Pilot Parvendra and EMT Ravindra Kumar promptly initiated a primary assessment. The patient, Mst. Satyam, a 7-year-old male, was found in critical condition among them. Mst. Satyam was with multiple injuries on the thigh and Left Leg femur fracture with lower leg laceration, profuse bleeding from the

injured area, and others had also serious injuries. The team applied direct pressure, dressed, bandaged and splinted the wound, and immobilized the limb to prevent further damage. After stabilization, the patients were rapidly transported to the CHC Maholi, District- Sitapur, for further care.

Pre-hospital management

108 Ambulance immediately arrived at the scene, where standard emergency medical protocols were initiated with a quick primary survey and initial assessment. The patients were carefully and safely extricated and secured within the ambulance using spinal precautions. Baseline vital parameters were recorded for Mst. Satyam pulse 85 bpm, respiratory rate 18 breaths per minute, blood pressure 110/70 mm Hg, temperature 98 °F, and SpO₂ 90% on room air, and skin condition were beyond the normal parameters. The patient had multiple abrasions and injuries on the body and a left leg fracture & profuse bleeding. The EMTs immediately initiated lifesaving interventions, including assessment and management of the airway, bleeding control via direct pressure, sterile wound dressing and bandaging. A splint was applied to

immobilize the injured limb, preventing further soft tissue and vascular compromise, with continuous monitoring of vital parameters. In the teleconsultation, the EMT administered medications as advised: Diclofenac injection for pain relief. Additional critical care measures were implemented as per further guidance from Dr. Satyanand. The patient was stabilized during transportation and later handed over to CHC Maholi, District- Sitapur, for further management.

Patient condition at the time of handing over:

Upon arrival at the hospital, the patient's condition had improved, as evidenced by stabilized vital signs.

Reflection of the patient or the patient's relative:

The patient was safely taken to CHC Maholi, Sitapur. The patient's family expressed deep appreciation for both the EMT and the Pilot, the swift response and efficient handling of the critical situation. It arrived on time and took the patient to the hospital on time, saving their life. We thank the ambulance staff and the government.



REFLECTION BY EMT : RAVINDRA KUMAR

"I handled this case based on the knowledge and skills I gained during my training. It is a matter of great joy and pride for me to receive the Saviour Award. This honour has inspired me to work even harder in the emergency service sector. I thank our organization from the bottom of my heart, which gave me this golden opportunity to serve. Also, I express special gratitude to my pilot, Mr Parvendra Singh, who supported me a lot in this life-saving mission."

REFLECTION BY PILOT : PARVENDRA SINGH

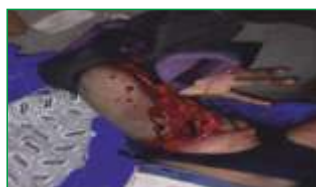"I am grateful that our case was chosen as "Saviours of the Month". In this case, I collaborated with EMT Mr Ravindra Kumar to provide proper care. I thank everyone who gave me this opportunity to participate in this noble work of saving lives and serving people. This experience gives me immense satisfaction and a sense of pride."



CASE DETAILS

PATIENT RECEIVING PRE-HOSPITAL CARE IN 108 AMBULANCES & MEDIA CLIPPING

AMBULANCE LOCATION : CHC-MAIGALGANJ, LAKHIMPUR KHERI
 CASE ID : 269111
 DATE : 09/12/2025
 CALL TIME : 17:12 HRS
 ERCP : Dr. SATYANAND
 RECEIVING HOSPITAL : CHC CHC MAHOLI DISTRICT-SITAPUR



Hon'ble Chief Minister of Odisha Shri Mohan Charan Majhi Launched
420 New 108 Ambulances on 23rd December 2025



BSNL Most Valued Customer
Award Received on
1st October 2025



Hon'ble Chief Minister of Tamil Nadu Shri. M.K. Stalin Launched
90 New 108 Ambulances on 1st November 2025



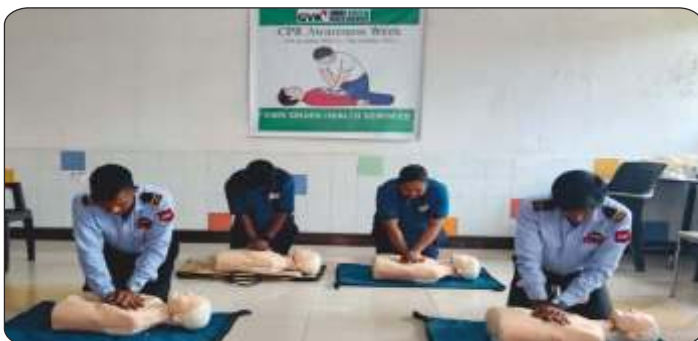EMRI GHS Honored for outstanding
Contribution in Emergency Healthcare
'Excellence in Life Saving Services'
Award on 16th October 2025



3 Days Leadership Workshop at EMRI GHS Hyderabad on 18th to 20th December 2025



CPR Awareness Week on 13th to 17th October 2025



Hon'ble Director of EMRI GHS Shri. K. Krishnam Raju Garu and Professor Ravi Anupindi Launched 3 Mobile Bike Workshops on 20th December 2025



Annual Reward and Recognition Program at Uttar Pradesh on 9th October 2025





EMRI GREEN HEALTH SERVICES

Devar Yamzal, Medchal Road, Secunderabad - 500 078 Telangana, India.

Tel : + 91 40 2346 2600, 2346 2602 - Fax 2346 2178

www.emri.in