

EM CARE

Towards saving lives and bringing hope



CALL 108
EMERGENCY
• MEDICAL • POLICE • FIRE

Spreading... **SMILE**

Partnering States and Union Territories



Government of Andhra Pradesh



Government of Telangana



Government of Gujarat



Government of the National Capital Territory of Delhi



Government of Goa



Government of Tamil Nadu



Government of Karnataka



Government of Kerala



Government of Assam



Government of Madhya Pradesh



Government of Odisha



Government of Uttarakhand



Government of West Bengal



Government of Arunachal Pradesh



Government of Jharkhand



Government of Uttar Pradesh



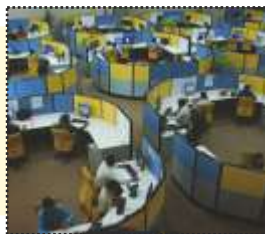Government of Rajasthan



Government of Dadra and Nagar Haveli Daman and Diu

Towards Saving Lives and Bringing Hope...

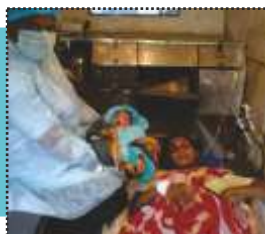Launched on 15th August 2005 in Hyderabad and expanded to 17 States and 1 Union Territory in India



94,622 CALLS ANSWERED EVERY DAY



39,479 EMERGENCIES RESPONDED PER DAY FLEET OF 9,205 AMBULANCES BY TRAVELLING DISTANCE OF 15.64 Lakhs KM PER DAY
35.53 Lakhs EMERGENCIES RESPONDED FOR (APR-JUN 2025)



79.83 Lakhs LIVES SAVED AND 6.82 Lakhs DELIVERIES ASSISTED BY EMTs SINCE INCEPTION



"EMTS AND PILOTS ARE THE BACKBONE OF GVK EMRI GHS"

Dear Team,

EMRI Green Health Services had a remarkable Q2 in 2025, marked by numerous national-level events that underscored its commitment to enhancing healthcare services across India.

In the Quarter of April – June 2025 saw several significant events. Hon'ble Chief Minister of Uttar Pradesh, Shri Yogi Adityanath, had launched 2554 New 108 ambulances. On April 01st, 2025. Furthermore, the Government of Rajasthan and EMRI GHS launched 10 new 108 ALS (Advanced Life Support) ambulances on April 07th, 2025. Additionally, A continuing Medical Education (CME) event was held at Osmania General Hospital on April 23rd, 2025.



EMT day was celebrated on 2nd April, and Pilot day was celebrated on 26th May across the organization. EMTs and Pilots were always considered the backbone of EMRIGHS. Special messages were circulated. EMTs and Pilots were appreciated by all stakeholders for their relentless services in the provision of out-of-hospital and point-of-care services. The media has also documented the special role of these ambulance staff who interface with the communities.

June 2025 was marked by several significant events. World Environment Day was observed on 5th June 2025, highlighting global efforts towards environmental protection and sustainability. The Rajo Festival celebrations took place in Odisha on 13th June 2025, showcasing the rich cultural heritage of the region. On 20th June 2025, Hon'ble Director of EMRI GHS, K. Krishnam Raju Sir, and his team visited Stanford University, likely fostering academic collaborations or exploring innovations. The month culminated with the celebration of International Yoga Day on 21st June 2025, promoting the practice of yoga for holistic health and well-being globally.

In these three months (from April to June 2025), Special Health day notes on World Health Day, International Mother's Day, International Nurses Day, World Veterinary Day, World Hypertension Day, World Blood Donors Day messages were published and widely circulated among EMRItes.

The Care Excellence initiative demonstrated significant progress through fortnightly meetings dedicated to enhancing prehospital care. Key focus areas included ePCR (electronic Patient Care Reporting), refinement of the OLMR (Online Medical Record) protocol, and assessment of EMT (Emergency Medical Technician) performance. Notable metrics indicated ePCR completeness stood at 79%, reflecting efforts to improve data capture and reporting. Additionally, Critical Cases and Medical Direction achieved a high rating of 94%, underscoring strong oversight and quality in medical decision-making and critical care handling.

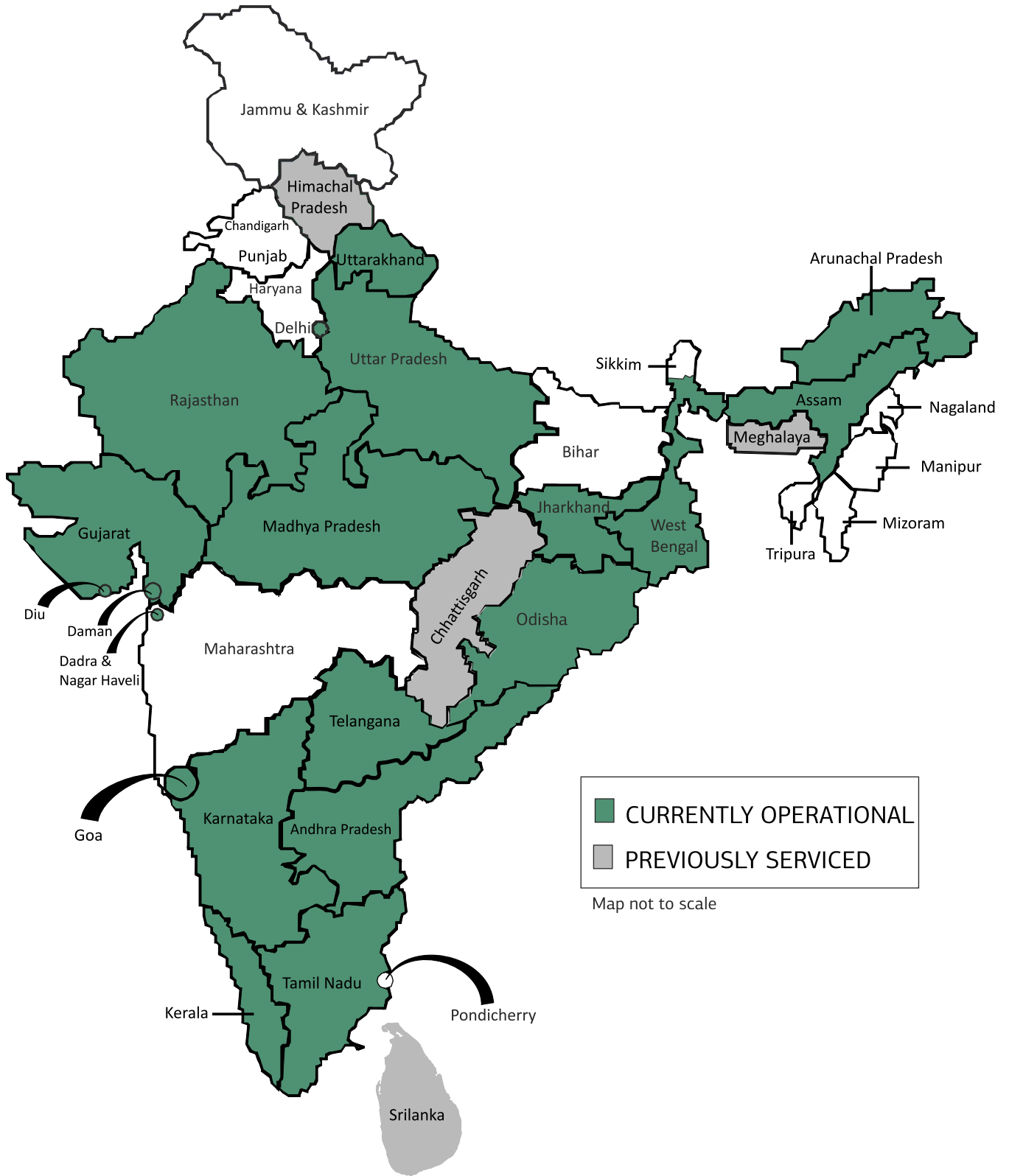
I extend my heartfelt congratulations to the exceptional teams of **Karnataka for April 2025, Tamil Nadu for May 2025 and Gujarat for June 2025** for receiving the Life Saviours Award. Your unwavering dedication and commitment to saving lives have made a remarkable impact, and this recognition is a testament to your exceptional work.

With best wishes

K. Krishnam Raju

DIRECTOR - EMRI Green Health Services





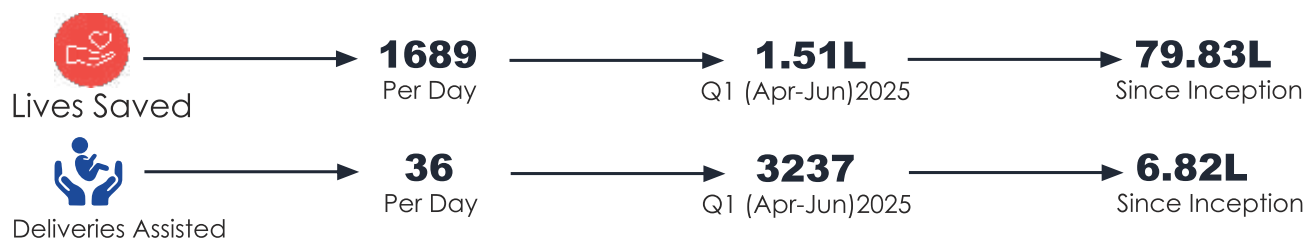

- 108 Emergency Response Center handles over 250,000 calls daily.
- An impressive 97% of calls are answered within just 2 rings.
- Initiated to lower neonatal mortality rates.
- Fully equipped (incubator- ventilator etc.) to facilitate the transfer of newborns between Special Newborn Care Units (SNCU) and Neonatal Intensive Care Units (NICU).
- Initiated to reduce infant and maternal mortality rates
- These ambulances are designed to transport pregnant women, mothers and newborn babies from home to hospital and hospital to home in sterile and safe environment
- Mobile Medical Units(MMU) provide primary health care on wheels.
- Serve medical needs of individuals in remote areas
- Introduced for rapid response to medical emergencies in riverine regions.
- Provide critical healthcare support during floods
- Primarily used to transit care patients from lower level to higher level hospitals in emergency situations.
- This innovative approach is designed to carry emergency patients navigate hilly terrains or no road connectivity
- Health helpline services in non-emergency
- This telemedicine service offers information, advice, and counseling
- Implements "Dial 100 Police" service to combat crime and maintain societal peace and safety
- It uses advanced technology to analyze calls, enhance information for rapid response, facilitate follow-up and expedite information sharing to different levels of law enforcement & prompt response.
- "Call 181" - Women Helpline is a dedicated service aimed at assisting women in distress
- Mobile Veterinary Units accessed through 1962 toll free no. provides doorstep point-of-contact- care (POCC) for livestock and stray animals.
- MVUs with Hydraulic lift to carry animals to veterinary facilities in few states

Physical Progress

108 State Wise Ongoing Projects:

S.No	Name of the State Government	No of Ambulance as on June 25	Emergencies Since Inception	Emergencies Attended in Q1 (Apr'25-June '25)
1	Telangana	626	95.59 Lakhs	1.92 Lakhs
2	Gujarat	874	178.51 Lakhs	3.48 Lakhs
3	Goa	101	9.08 Lakhs	0.19 Lakhs
4	Tamil Nadu	1,394	182.4 Lakhs	4.45 Lakhs
5	Karnataka	715	117.71 Lakhs	1.4 Lakhs
6	Assam	800	71.11 Lakhs	0.99 Lakhs
7	Diu Daman & Dadra Nagar Haveli	22	4.77 Lakhs	0.1 Lakhs
8	Uttar Pradesh	2,200	408.36 Lakhs	17.28 Lakhs
9	Rajasthan	1,094	59.55 Lakhs	1.4 Lakhs
10	Kerala	316	11.24 Lakhs	0.5 Lakhs
11	Delhi	87	19.72 Lakhs	0.37 Lakhs
12	Arunachal Pradesh	110	0.3 Lakhs	0.03 Lakhs
13	Odisha	866	9.37 Lakhs	3.42 Lakhs
	Q1 FY-2025-26	9,205	1167.72 Lakhs	35.53 Lakhs
Average Emergencies Attended Per Day				0.39 Lakhs



Janani Shishu Suraksha Karyakram (JSSK) State Wise Ongoing Projects:

S. No	Name of the State Government	No of Janani Ambulance as on June 2025	Janani Beneficiaries Since Inception	Janani Beneficiaries in Q1 (Apr'25-June'25)
1	Gujarat	432	132.3 Lakhs	4.7 Lakhs
2	Telangana	300	77.09 Lakhs	2.41 Lakhs
3	Uttar Pradesh	2,270	1014.24 Lakhs	43.9 Lakhs
4	Goa	4	0.11 Lakhs	0 Lakhs
5	West Bengal	928	51.92 Lakhs	1.78 Lakhs
6	Tamilnadu	130	21.14 Lakhs	0.82 Lakhs
7	Odisha	500	2.3 Lakhs	0.88 Lakhs
	Q1 Total	4,564	1299.15 Lakhs	53.68 Lakhs
Average Emergencies Attended Per Day				0.59 Lakhs

“Over the tenure spanning from 2008 to 2025, the **108** completed projects across 8 states collectively handled more than **1.66 crore emergencies**, assisted over **1.43 lakh deliveries**, and helped **save 6.5 lakh Lives** - underscoring EMRI's enduring contribution to lifesaving care across India.”

“Between 2014 and 2023, the JSSK projects completed across **3 states** supported **over 97 lakh mothers and children**, ensuring safer access to healthcare and reinforcing EMRI's commitment to maternal & child well-being across states.”





108 Saviour of EMRI GHS - INDIA

APRIL 2025	: KARNATAKA TEAM – A CASE OF SUICIDE ATTEMPT	08
MAY 2025	: TAMIL NADU TEAM – A CASE OF TRAIN ACCIDENT	17
JUNE 2025	: GUJARAT TEAM – A CASE OF COMPLICATED DELIVERY	26

STATE WISE CASE OF THE MONTH

APRIL	: ASSAM TEAM – A CASE OF RTA	09
APRIL	: GUJARAT TEAM – A CASE OF MEDICAL EMERGENCY (ANAPHYLAXIS)	10
APRIL	: KERALA TEAM – A CASE OF TRAIN ACCIDENT	11
APRIL	: TAMIL NADU TEAM – A CASE OF FALL FROM HEIGHT	12
APRIL	: TELANGANA TEAM – A CASE OF RTA	13
APRIL	: UTTAR PRADESH TEAM – A CASE OF SHORTNESS OF BREATH (SOB)	14
MAY	: ASSAM TEAM – A CASE OF FALL FROM HEIGHT	17
MAY	: GOA TEAM – A CASE OF RTA	18
MAY	: GUJARAT TEAM – A CASE OF OP POISONING	19
MAY	: KARNATAKA TEAM – A CASE OF RTA	20
MAY	: KERALA TEAM – A CASE OF PRE-TERM DELIVERY	21
MAY	: TELANGANA TEAM – A CASE OF ELECTROCUTION	22
MAY	: UTTAR PRADESH TEAM – A CASE OF NEONATAL RESUSCITATION (NNR)	23
JUNE	: ASSAM TEAM – A CASE OF RTA	26
JUNE	: GOA TEAM – A CASE OF NORMAL DELIVERY	27
JUNE	: KARNATAKA TEAM – A CASE OF RTA	28
JUNE	: KERALA TEAM – A CASE OF FALL FROM HEIGHT	29
JUNE	: TAMIL NADU TEAM – A CASE OF FALL FROM HEIGHT	30
JUNE	: TELANGANA TEAM – A CASE OF SUICIDE ATTEMPT	31
JUNE	: UTTAR PRADESH TEAM – A CASE OF TRAIN ACCIDENT	32

NOT FOR PROFIT ORGANISATION OPERATING IN PUBLIC PRIVATE PARTNERSHIP MODEL



A CASE OF SUICIDE ATTEMPT

Details of the incident :

On 19th April 2025 at 18:16 hrs, Ms. Bhagyashree 14-year-old female attempted suicide by jumping off in front of the Train at Yadgir railway station of Yadgir district. Emergency Response Center (ERC) received a call from a good Samaritan from railway station, who was very frightened and requested for an ambulance urgently, on asking about case details our Emergency Response Officer (ERO) dispatched nearest available ambulance Yadgir District Hospital location which had completed a case and had made a release call (R Call) to ERC stating that they were ready to take the next case. The case was immediately assigned to ambulance manned with EMT Mr. Kashinath and Pilot Mr. Mallikarjun on duty and they reached the victim location which was 10 km's away within 19 minutes of duration.

Diagnosis or condition :

When the 108-crew arrived at the scene EMT found that victim was a 14 year old,

presented with altered menta status due to head injury & both lower limbs were amputated. It was very challenging for the crew to handle such victim & anxious crowd who had witnessed the breath-taking event with the support of Railway Police shifted to the ambulance with amputated limb part. The incident was handled by 108 crew in a calm & composed professional way while dealing with the victim.

Pre Hospital Care Management:

Without delaying EMT & Pilot started shifting the critically injured young victim by means of bleeding controlled through direct pressure method & splint was applied. Amputated ankle part was wrapped and placed in the sealed cover & shifted with spine board into the ambulance. While transporting vital signs were recorded that Temperature 98.4 F, Pulse- 106/min, RR- 26breaths/min, BP- 100/60mmof Hg, saturation- 91% and GRBS-92mg/dl. Mean while ERCP Dr. Harsha was briefly described the event. IV fluids started,

oxygen 6 liters/minute administered, C-collar applied ,supine position maintained and shifted to the Yadgir district hospital.

Patient condition at the time of handing over:

Hospital doctors appreciated EMT & Pilot for their presence of mind and the accurate pre hospital management which was given to the victim on scene & in the ambulance before reaching to the hospital. The victim was immediately attended by a Team of Doctors for further evaluation of the victim condition.

Reflection of the patient or patient relative:

Victim's parents & relatives & few of the on lookers showered blessing and showed gratitude towards our ambulance team. Condition of the victim was stable during 48 hour follow up call. The Victims was shifted to the higher facility center for further surgical care.



REFLECTION BY EMT : KASHINATH

"It was a very challenging case for me, and I felt very much satisfied after shifting the victim from the railway track to the hospital within the golden hour. It gives tremendous pleasure to serve people when they need our help & support. I am thankful to EMRI GHS for giving me the opportunity to save a life in need. Honesty & integrity are the essence of a satisfied life, which I felt after handing over a young life safely."

REFLECTION BY PILOT : MALLIKARJU NAIK

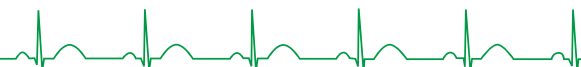"I am happy because I took part in Pre Hospital Care & I was able to shift the patient on time to hospital which made the work of doctors and other staff to treat effectively and I would like to say thanks to EMRI GHS for giving me an opportunity to work as a Pilot in 108 Ambulance to serve the community."



CASE DETAILS

AMBULANCE LOCATION : YADGIR DH
 CASE ID : 989771
 DATE : 19/04/2025
 CALL TIME : 18:16 HRS
 ERCP : Dr. HARSHA
 RECEIVING HOSPITAL : YADGIR DH

PATIENT RECEIVING PRE-HOSPITAL CARE IN 108 AMBULANCE & MEDIA COVERAGE



APRIL 2025

A CASE OF RTA

Details of the incident:

The call was received at the ERC requesting for the help and save the 27 years old victim. Receiving the case ERO assigned the case to Barbaruah Location of Dibrugarh District, at 17:07 hrs. The team comprising of EMT Mr. Gokul Missong and Pilot Mr. Rajib Das, rushed to the scene.

Diagnosis or condition:

27-year-old, Mr. Rahul Saikia is a worker in a private company. On 14th April, he was on the way to his home from duty, meanwhile a running auto hit him from behind very forcefully and ran away from the spot. Mr Saikia fell hardly and injured badly. After controlling the situation, EMT done rapid trauma assessment and found the victim

in semiconscious mode, also EMT observed many injuries on multiple regions and fractured both sides of Tibia bones. Without delay, EMT immediately stopped the bleeding by applying pressure bandage and took him inside the ambulance on a spine board with the help of Pilot and some bystanders.

Pre-Hospital management:

At scene Vitals were monitored by EMT and recorded the vitals as, BP-120/70 mmHg, PR-80 bpm, RR-20/minutes, SPO2-98. EMT placed the patient in a comfortable position and took ERCP advice from Dr. Anupam Borgohain. According to ERCP advice he connected IV fluid NS, Injected pain killer, applied splint

to the fractured areas and proper dressing was done in all injures areas.

Patient condition at the time of handing over:

After providing the Pre-hospital care, Enroute EMT kept constant monitoring on the patient. Enroute to the hospital, vitals were recorded as BP-120/80 mmHg, PR-82 bpm, RR-20 bpm, SPO2-98 and she was handed over to Assam Medical College and Hospital

Reflection of the patient or patient relative:

Victim was in critical condition. His family member praised the EMT for the fast response and Pre-Hospital care given by him.



REFLECTION BY EMT : GAKUL MISSONG

“It was great experience handling the RTA case where we could save a precious life. As per the severity of the case it was quite scary as the Tibia bones were completely fractured. The advice of ERCP help me build up my confidence level more to intervene the victim and give relief.”

REFLECTION BY PILOT : RAJIB DAS

“Our EMT sir was managing the serious case while I was driving the Ambulance in such a crowded street and handed over the patient in proper time to the destination hospital. ”



CASE DETAILS

AMBULANCE LOCATION : BARBARUAH, DIBRUGARH
 CASE ID : 20250400074962
 DATE : 14/04/2025
 CALL TIME : 17:07 HRS
 ERCP : Dr. ANUPAM
 RECEIVING HOSPITAL : ASSAM MEDICAL COLLEGE & HOSPITAL

PATIENT RECEIVING PRE-HOSPITAL CARE IN 108 AMBULANCE & MEDIA CLIPPING



A CASE OF MEDICAL EMERGENCY (ANAPHYLAXIS)

APRIL 2025

Details of the incident:

On 12th April 2025, our Bhandu location team received a call from a bystander who noticed that Ishwarlal was attacked by a swarm of honey bees in an open field. EMT gave pre arrival instructions to the bystander to be careful & prevent others from entering the unsafe scene and to try to move the patient away from incident site only if it was safe to do so.

Diagnosis or condition:

On arrival at scene, EMT found that bees continued to swarm around the patient thus making direct access hazardous for anyone. EMT and Pilot carefully approached the patient by wearing an appropriate PPE kit and rescued him away from the swarm zone by using soap water and sanitizer. Patient had severe

burning pain and swelling due to multiple stings on several areas of the body including arms, neck and face. Patient had breathlessness, headache & dizziness along with nose and ear bleeding caused due to the bees entering patient's nose & ear & stinging from within.

Pre-hospital management:

EMT Rina Patel immediately transferred patient into the ambulance and started oxygen administration through face mask. EMT noticed that some bees were still inside the patient's clothes and had also entered the nose and ear of patient. EMT removed those bees by hand held suction from Nose and removed the stingers from the body by using ID card. EMT accessed two lines and assessed vital signs which were as follows: SpO2 89%,

Respiration Rate 28 breaths/min, Pulse Rate 144 beats/min, Blood Pressure 80/50 mm of Hg and RBS 60 mg/dl. EMT contacted Emergency Response Center Physician - Dr. Roopchand Ramani and as per his advice, EMT continued Oxygenation and administered Inj. Avil, Inj. D 25% and IV RL 500 ml.

Patient's condition at the time of handing over:

After implementing all necessary interventions and with continuous monitoring, patient was shifted to Sub District Hospital, Unjha. At the time of handing over, patient's condition was stable.

Reflection of the Bystander:

The relatives appreciated the care given by EMT and Pilot which eventually saved this patient's life.



REFLECTION BY EMT : RINA PATEL

"I am extremely happy and grateful as our case has been selected as savior. We have worked very hard and put all the efforts to save life. I also thank my Pilot for helping me in this life saving mission as our team work definitely helped us in managing this challenging case."

REFLECTION BY PILOT : YOGI SANDIPKUMAR

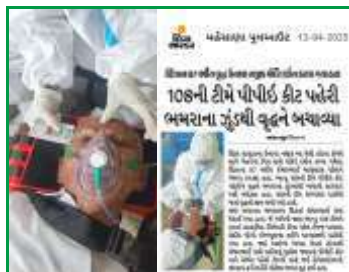"I feel very proud and can't find the words to express my feelings for being selected as a Savior for the first time. I have been eagerly waiting since long for our work to be appreciated with a Savior Award. This encourages me to work enthusiastically and more confidently. I am very lucky to be associated with the EMRI GHS Organization. "



CASE DETAILS

AMBULANCE LOCATION : BHANDU
 CASE ID : 20250400082613
 DATE : 12/04/2025
 CALL TIME : 10:33 HRS
 ERCP : Dr. ROOPCHAND RAMANI
 RECEIVING HOSPITAL : SUB DISTRICT HOSPITAL, UNJHA

PATIENT RECEIVING PRE-HOSPITAL CARE IN 108 AMBULANCE & MEDIA CLIPPING



APRIL 2025

A CASE OF TRAIN ACCIDENT

Details of the incident:

The Vellarada CHC ambulance was dispatched to respond to a call regarding a trauma case a train accident. The victim, a 27-year-old woman, was the caller. According to her, she was a passenger on a train, standing near the door and she slipped and fell outside the running train. She fell into a deserted area and couldn't identify the location herself and our EMT advised her to share her live location. Based on the location shared, the scene was 20 km away from the base location. Our team reached the scene as quickly as possible, despite having limited information about the location. Locating the victim was challenging due to poor visibility at night. After an extensive search, they successfully located her near the railway track with the help of the flashlight on her mobile phone.

Diagnosis or condition:

The EMT quickly assessed the patient's condition. Patient was in altered sensorium, had severe head injury

externally i.e. lacerated wound over the occipital area, suspected head injury, severe hemorrhage, and back pain indicated suspected spinal cord injury. Other conditions included hemorrhagic shock, hypotension, and mild respiratory distress

Pre-hospital management:

Patient was shifted into the ambulance and monitored the vital signs. The saturation was 96%, Blood Pressure 80/60mmhg, Pulse Rate 80b/m, and the Respiration was 18bts/m. realizing this, EMT has started to provide pre hospital care en-route such as SMRD technique to prevent further spinal code injury, IVF NS 500ml bolus IV given, and dressing was done for bleeding control. Patient was immediately shifted to Govt. Medical College Hospital, Thiruvananthapuram.

Patient's condition at the time of handing over:

After implementing the necessary interventions and continuous monitoring the patient, the EMT observed slight

improvement in the patient's condition. The breathing problem became normal with oxygen support, and the patient was apparently better symptomatically. Vital signs, such as blood pressure, heart rate and saturation got better. The EMT ensured that the patient was secured on the ambulance and given care according to that. EMT prepared for a smooth handover to the hospital staff upon arrival.

Reflection of the patient or patient relative:

Patient family member expressed gratitude for the EMT's prompt response and effective management of the breathing and airway management. They appreciated the Pilot and EMT's professionalism, good action to the emergency, and the reassurance provided during a distressing situation. Family members acknowledged the importance of the swift actions taken by the EMT and Pilot, which contributed to the positive outcome and alleviated their concerns during the ambulance journey

**REFLECTION BY EMT : CHINCHU**

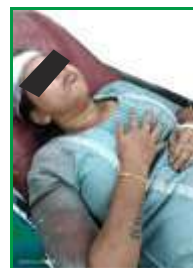"It was a challenging situation and when we arrived at the scene, the patient was very weak and tired, though there was an initial struggle in locating the patient in such a remote area in the dark, with the patient's courage and cooperation we could locate her and we gave all the possible pre hospital care to save her. It gives us immense joy that we could save her from such a tragic situation."

REFLECTION BY PILOT : RATHEESH S

"Locating the patient was challenging due to poor visibility at night, still we tried our best and did provide required care. And without causing any delay, we shifted the patient to Trivandrum MCH. Feeling much grateful for being able to be life savors in this situation."

**CASE DETAILS****PATIENT RECEIVING PRE-HOSPITAL CARE IN 108 AMBULANCE**

AMBULANCE LOCATION : VELLARADA CHC
 CASE ID : 20250400075251
 DATE : 23/04/2025
 CALL TIME : 22:17 HRS
 ERCP : Dr. ANAKHA SAJEEV
 RECEIVING HOSPITAL : GOVT. MEDICAL COLLEGE HOSPITAL,
 THIRUVANANTHAPURAM



A CASE OF FALL FROM HEIGHT

APRIL 2025

Details of the incident:

On April 4, 2025 at around 12:25 pm, a Good Samaritan called our Emergency Response Centre to report an incident involving a 43-year-old male who fallen accidentally from 18 feet height when he climbed on the coconut tree.

He requested our ambulance to rescue the victim as he was injured severely. Immediately our Emergency Response Officer assigned the case to Thirukoshtiyur location ambulance for an immediate support. Ambulance crew reached the scene within few minutes and rescued the victim to the safest place.

Diagnosis or condition:

Upon arrival, the EMT assessed the level of conscious of the victim and found that the victim was conscious and oriented. He had a complaints of

severe back pain, breathlessness, pain in the centre of the chest and sweating

Pre-hospital Management:

The victim was placed in a Supine position, Head and spine was immobilized with spinal movement restriction devices of C-Collar, spine board with straps and head blocks. With proper spinal immobilization, the victim was loaded into the ambulance. vital Parameters were checked and recorded as HR-80 bt/min, RR-24 br/min, BP-90/60mm Hg, Temp-98.6 F, Pupils-PERL and SPO2-90%. oxygen administered via simple face mask and IV cannula was inserted.

Enroute, ERCP advice taken and IV fluids were administered as per ERCP advice. Vital parameters were monitored every 5 minutes once.

Victim was reassessed for any potential complications due to spinal injury. the victim was safely transported to Government Medical College Hospital, Sivagangai

Patient's condition at the time of handover:

At the time of handover, the victim conscious and oriented. Vital parameters were improved to normal range. During the time of admission, the victim experienced severe back pain and he got safely admitted to the hospital.

Reflection of the Patient's relative:

Victim's spouse thanked our EMT and Pilot for the care provided by them. They were very kind and gentle while handling the case and it was a unforgettable grateful moment in my life.



REFLECTION BY EMT : VIJAYALAKSHMI

"At scene, the victim was found in a state of panic. My Pilot helped me a lot in rescuing and transporting the victim. ERCP guided well in providing a good pre hospital Care."

REFLECTION BY PILOT : MANIMARAN

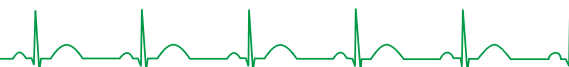"I assisted the EMT in application c collar, Spine board and the head blocks. I swiftly and safely transported the victim to the hospital with right time."



CASE DETAILS

PATIENT RECEIVING PRE-HOSPITAL CARE IN 108 AMBULANCE

AMBULANCE LOCATION : THIRUKOSHTIYUR PHC
 CASE ID : 38221
 DATE : 04/04/2025
 CALL TIME : 12:25 HRS
 ERCP : Dr. MEERA
 RECEIVING HOSPITAL : GOVERNMENT MEDICAL COLLEGE HOSPITAL, SIVAGANGAI



Details of the incident:

On April 4, a truck carrying oil pockets overturned after hitting a road divider on its way to Hyderabad city from Kazipet, Warangal district. The accident left two people seriously injured. A 40-year-old man, Mr. Ramakrishna, suffered a complete traumatic amputation of his left hand and experienced severe blood loss.

Diagnosis or Condition:

Local citizens quickly called the 108 emergency service. Within minutes, the 108 crew arrived, took full personal protective care, and immediately attended to the victim. The EMT and Pilot found that the victim Mr. Ramakrishna had severe injury to his left upper extremity and from injury severe bleeding is going on.

Pre-Hospital Care or Management:

Out Ambulance Team EMT Mr. Mahender with help of Pilot Mr. Srinivas, controlled the profuse bleeding from Mr. Ramakrishna's amputated left arm with large gauze pads at scene. Later they took decision of transferring the victim on scene with help SMRD by lifting and moving techniques carefully. Inside the ambulance, the crew took further life-saving measures. They begin administering oxygen, placed the patient in a shock position, and monitored his vitals. After consulting with an ERCP Dr. Srikanth the ambulance team started a Normal Saline IV and administered 100mg of Tramadol for pain. A rapid trauma assessment was also performed to check for internal injuries. The patient was then safely transferred to the Government

General Hospital of Siddipet District. (old Medak District)

Reflection of the Patient or Patient relative / villagers and Hospital staff:

Following the incident, the patient and a relative expressed their gratitude to the 108 ambulance staff.

Patient Reflection: Ramakrishna stated that he was alive only because of the 108 ambulance staff. He thanked them for arriving on time and providing immediate treatment, including bandaging his wounds and providing oxygen and glucose.

Family/Villagers Reflection: The patient's family and the villagers also expressed gratitude for the staff's prompt response and immediate medical assistance.



REFLECTION BY EMT : MAHENDER

"The emergency call on April 4 detailed an overturned truck with serious injuries, which put the EMT's training into focus. Upon arrival, Ramakrishna had a traumatic left hand amputation and significant blood loss. The EMT stayed calm, using the hours of practice and drills. The immediate priority was to control the profuse bleeding, which required quick action. Stabilizing the patient for transport was intense. It is gratifying to hear later that these actions made a life-saving difference, underscoring the importance of a rapid and professional response in high-stakes situations."

REFLECTION BY PILOT : SRINIVAS

"Every emergency call is a race against time, as this incident highlighted. The pilot's job is to get their partner and the ambulance to the scene quickly and safely, navigating traffic and difficult terrain to save time. On April 4, the call for the truck accident was urgent. Knowing that the driving and navigation played a vital part in getting the EMT partner to the patient in time to provide life-saving care is a source of immense professional satisfaction. This incident highlights the critical teamwork between the pilot and the EMT, where every action contributes to the overall success of the mission."



CASE DETAILS

PATIENT RECOVERY PHOTOGRAPHS & MEDIA CLIPPING

AMBULANCE LOCATION : NANDI GAMA
 CASE ID : 6049965
 DATE : 08/04/2025
 CALL TIME : 15:28 HRS
 ERCP : Dr. SRIKANTH .P
 RECEIVING HOSPITAL : GOVERNMENT GENERAL HOSPITAL,
 SIDDIPET.



A CASE OF SHORTNESS OF BREATH (SOB)

APRIL 2025

Details of the incident:

Kanchan's 3-month-old child from Kopaganj block was recently diagnosed with pneumonia. The infant developed severe breathing difficulties and seizures, prompting the family to rush him to the district hospital. After a thorough assessment, the attending doctors recognized the critical nature of the condition and immediately recommended advanced medical care. A 108 ambulance was promptly called, and the child was urgently referred to Azamgarh PGI for specialized treatment.

Diagnosis or condition:

Upon reaching the location, EMT Amit promptly transferred the child to the ambulance. At that time, the child's oxygen saturation was critically low at just 58%, and the pulse rate was recorded at 128 bpm. Recognizing the severity of the situation, EMT Amit reported that the infant was in a highly critical condition. Following standard protocol, he immediately contacted ERCP Dr. Satya for online medical guidance. Acting on Dr.

Satya's instructions, EMT Amit Kumar Sharma initiated oxygen support using an Ambu bag right inside the ambulance to stabilize the child during transport.

Pre-Hospital management:

Inside the ambulance, EMT Amit swiftly transferred the infant onto the stretcher. The child's oxygen saturation was critically low at only 58%, and the pulse rate was recorded at 128 bpm. Recognizing the severity of the situation, EMT Amit immediately stated that the baby's condition was very critical. The child's respiratory rate was 28 breaths per minute, pulse at 106 bpm, SPO₂ was 84%. Understanding the urgency, EMT Amit immediately contacted Dr. Satya, who was stationed at the call center. After receiving guidance from Dr. Satya, EMT Amit began administering oxygen to the child using an ambu bag at 10 to 15 LPM. In addition, Dr. Satya emphasized the importance of transporting the child to the hospital as quickly as possible.

Throughout the journey, EMT Amit

continued to administer oxygen, using his judgment while following the doctor's advice. Dr. Satya maintained constant communication with EMT Amit, offering support and ensuring that the child received appropriate care during transit.

Patient's condition at the time of handing over:

After implementing all necessary interventions and with continuous monitoring baby were shifted to Azamgarh PGI after travelling for a distance of approximately 20 km. At the time of handing over, both the mother and baby were stable and Doctor also appreciated the efforts of EMT and Pilot for giving the best possible care and saving lives.

Reflection of the patient or patient's relative:

The relatives tremendously appreciated the care given by EMT and Pilot which eventually saved mother and baby's lives and were thankful to the 108 ambulance services.



REFLECTION BY EMT : AMIT

"I am extremely happy to have been selected as the Savior for the first time. I handled this case with the knowledge and skills attained during my training. Receiving savior award has given me happiness and motivation to keep working hard in emergency field. I really thank our organization for giving me an opportunity to serve. I also thank my Pilot Ramprit for helping me in this life saving mission. "

REFLECTION BY PILOT : RAMPRIT

"I am grateful, as our case has been selected as the savior of the month. In this case, I helped EMT Amit in providing Care to both Newborn and Mother. I thank all who have given me this opportunity for saving lives and serving people. This really gives me lots of satisfaction."



CASE DETAILS

AMBULANCE LOCATION : CHC KOPAGANJ
 CASE ID : 339696
 DATE : 12/04/2025
 CALL TIME : 15:00 HRS
 ERCP : Dr. SATYA
 RECEIVING HOSPITAL : DISTRICT AZAMGARH PGI
 DISTRICT: AZAMGARH

PATIENT RECEIVING PRE-HOSPITAL CARE IN 108 AMBULANCE & MEDIA CLIPPING



MAY 2025

A CASE OF TRAIN ACCIDENT

MAY 2025

Details of the incident :

On 24th May 2025 our Emergency Response Centre received a call for a 28 years old male who has a amputation of his right hand below shoulder. When he was travelling in a train ,due to overcrowding of the compartment he was sitting at the door. After some time , he fall asleep and fell down from the moving train and got severely injured. Immediately our Emergency Response Officer assigned the case to Rayakottai Fire Station location ambulance for thesupport.

Diagnosis or condition :

Upon arrival , the EMT assessed the level of conscious of the victim and found that the victim was conscious and oriented .He had the complaints of left leg amputation with severe bleeding and abrasion in abdomen.

Pre-hospital Management :

The victim was placed in a Supine position,vital parameters were checked HR-66 bt/min, RR-16 br/min, BP-90/60mm Hg, Temp-98.8 F , Pupils-PERRL and SPO2-90% and it was observed as unstable. At scence, bleeding was contolled effectively , Wound was cleaned with saline and pressure dressing applied. Immediately, the victim was loaded in to the ambulance with the help of scoop board along with secured amputated part. Oxygen was administered through Simple face mask and large bore 18G IV cannula inserted.

Enroute, ERCP advice taken, and IV fluids were administered as per ERCP advice. Vital parameters were checked and recorded every 5 minutes once. Victim was reassessed for any life threatening condition and

he was safely transported to Government Medical College Hospital, Krishnagiri .

Patient's condition at the time of handover :

At the time of handover, victim is conscious and oriented. Vital parameters were stable HR-70 bt/min, RR-18 br/min, BP-100/70mm Hg, Temp-98.8 F , Pupils-PERRL and SPO2-96%. During the time of admission, the secured amputated part was handed over to the hospital staff and it was properly documented.

Reflection of the public :

This victim was rescued with the help of police and railway team assoiates. They were also coordinated with our team in rescue the victim to the safest place and they have appreciated our service for the instant care provided for the victim his dangerous situation .



REFLECTION BY EMT : SANTHOSH

" It was very challenging to walk the distance of 1 km to reach the victim spot, after providing the necessary pre hospital care, we saved his precious life on time. "

REFLECTION BY PILOT : ARASU

" It was a great satisfaction for helping the victim in his critical situation. Thanks to 108 Ambulance service for providing such oppurtunities in saving lives. "



CASE DETAILS

INCIDENT & PATIENT RECEIVING PRE-HOSPITAL CARE IN 108 AMBULANCE

AMBULANCE LOCATION : RAYAKOTTAI FIRE STATION
 CASE ID : 274935
 DATE : 24/5/2025
 CALL TIME : 07:25 HRS
 ERCP : Dr. NISHITHA
 RECEIVING HOSPITAL : GOVERNMENT MEDICAL COLLEGE HOSPITAL, KRISHNAGIRI



Details of the incident:

The call was received at the ERC requesting for the help and save the 55 years old victim. Receiving the case ERO assigned the case to Goronga Location of Golaghat District, at 12:04 hrs. Sensing the situation, EMT Akhtar Alom quickly took details of the case, and became active and prepared for the case. Pilot Mujibur Rahman rushed the Ambulance towards the scene.

Diagnosis or condition:

On reaching the scene, EMT found that it was a case fall from height. 55-year-old Montu Sonowal is a construction worker. On 25th May 2025, in the afternoon, he had fallen from a height of 11-12 foot of a under construction building, while he was working in that construction area. After controlling the situation,

EMT done rapid trauma assessment and found the victim in semiconscious mode, also EMT observed active bleeding from his mouth and ear. His Spine got severely injured and EMT suspected it as fractured. Without delay EMT quickly controlled the bleeding thus managing the wound. He immobilized the affected part and used cervical collar to prevent from further injury of the spinal region and took him inside the ambulance on a spine board with the help of Pilot and some bystanders.

Pre-Hospital management:

At scene Vitals were monitored by EMT and recorded the vitals as, BP-110/80 mmHg, PR-84 bpm, RR-14/minutes, SPO2-96. EMT placed the patient in a supain position and took ERCP advice from Dr. Dilip

Sarmah. According to ERCP advice he connected IV fluid and proper dressing was done in the injury areas.

Patient condition at the time of handing over:

After providing the Pre-hospital care, Enroute EMT kept constant monitoring on the patient. Enroute to the hospital, vitals were recorded as BP-111/81 mmHg, PR-84 bpm, RR-16 bpm, SPO2-96 and he was handed over to Kushal Konwar Civil Hospital, Golaghat.

Reflection of the patient or patient relative:

Victim was in critical condition. His family members are pleased by the efforts of the EMT. The effort of the pilot was exceptional as he quickly and safely drove to scene and hospital.



REFLECTION BY EMT : AKHTAR ALAM

“When I reached the scene and saw the victim I was little scary but the knowledge and skill that I had acquire during the training helped me a lot to tackle the case. The case was different from the usual one regarding the mechanism of injury. Mostly fall from height threaten the injury of spine. I was happy that I could save a life.”

REFLECTION BY PILOT : MUJIBUR RAHMAN

“The praise and appreciation from the doctors of KKCH has really feel us proud that our job of saving lives is holy and divine. Thanks to all the authorities who are engage in running and administering the project.”



CASE DETAILS

PATIENT RECEIVING PRE-HOSPITAL CARE IN 108 AMBULANCE & MEDIA CLIPPING

AMBULANCE LOCATION : GORONGA
 CASE ID : 20250500123132
 DATE : 25/05/2025
 CALL TIME : 12:04 HRS
 ERCP : Dr. DILIP
 RECEIVING HOSPITAL : KHUAHAL KONWAR CIVIL HOSPITAL, GOLAGHAT



A CASE OF RTA

MAY 2025

Details of the incident:

On 29th may 2025 at 10:11 hrs, our emergency response center received a call from Coqueiro-Calangute, stating that there was a road traffic accident of a 2-wheeler collided with a truck. CCA Panjim ambulance was nearest available ambulance. After taking scene details, EMT and Pilot rushed to the scene with the relevant equipments to provide necessary Pre-hospital care. En route towards the scene, EMT advised caller to control any external bleeding of patient with direct pressure and not to feed him anything orally. Ensuring scene safety and maintaining BSI precautions, our team reached on the scene.

Diagnosis or condition:

After assessing scene safety, EMT and pilot approached patient. On arrival at the scene, the patient was

found conscious and oriented, with a severe open fracture and heavy bleeding in the left knee region, along with exposed tissues. EMT began a quick rapid trauma survey and found that the patient was having left open knee fracture with crush injury and active bleeding. Patient was 60-year-old male. Immediately wound care was given to the patient and external bleeding was controlled. Splint was applied to the fractured extremity.

Pre-hospital management:

patient was shifted in the ambulance on spine board. Without wasting time, EMT recorded vitals. Initial assessment revealed vital signs: BP 100/70 mmHg, Pulse 120 bpm (thready distal pulse), Respiratory Rate 14/ min, SpO₂ 97%, RBS 127 mg/dL. The patient was a known case of diabetes mellitus and

hypertension. ERCP call could not be connected. IV access was established by EMT A, and Normal Saline infusion was started.

Wound care was given to the patient.

Patient condition at the time of handing over:

After implementing the necessary interventions and continuously monitoring the patient, the EMT observed an improvement in the patient's condition. EMT gave reassurance to the patient. Meanwhile ambulance reached the destination hospital. Patient was handed over in the casualty of PHC Calangute.

Reflection of the patient:

Thank you to the ambulance team!



REFLECTION BY EMT : THACHINAMOORTHI CHINNU

"It was a challenging case, and we took extra care while handling this particular victim. The victim was bleeding when we arrived at the scene. But we gave the victim and the relatives reassurance and gave all the possible pre-hospital care to save the victim's life. I feel proud that our timely intervention saved the life of the patient, and we could shift the victim to the hospital safely."

REFLECTION BY PILOT : GOVIND LAXMAN CHOUGULE

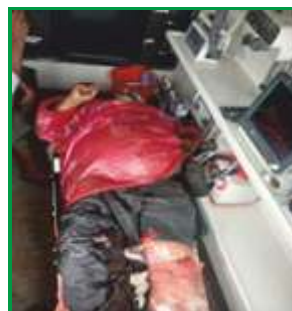
"We provided the required pre-hospital care to the patient by following all protocols and transferred the patient on time to the hospital, thereby saving the victim's life. Thanking EMRI GHS for allowing me to save the lives of others."



CASE DETAILS

PATIENT RECEIVING PRE-HOSPITAL CARE IN 108 AMBULANCE

AMBULANCE LOCATION : CCA PANJIM, NORTH GOA
 CASE ID : 20250500023829
 DATE : 29/05/2025
 CALL TIME : 10:11 HRS
 RECEIVING HOSPITAL : PHC CALANGUTE



MAY 2025

A CASE OF OP POISONING

Details of the incident:

On 24th May, 2025, 40 years old Nareshbhai, a resident of Chhota Udepur district, attempted suicide by drinking Pesticide poison. As soon as his family members came to know about this they dialed 108 for help. The Tejgadh location team quickly reached to the incident location after providing proper pre-arrival instructions to change his clothes if poison was spilled on his clothes, to keep him in left lateral position and to not give him anything orally.

Diagnosis or condition:

On arrival at scene, Nareshbhai was found to be in Unconscious Status with bradycardia, bradypnea, hypoxia, frothing from mouth and BP was not recordable.

Pre-hospital management:

EMT Rekha immediately started airway management with suction, maintained it with Nasopharyngeal Airway and started bag valve mask ventilations. EMT promptly loaded him into the ambulance with the help of pilot and relatives. In ambulance, EMT continued BVM with high flow oxygenation, and also took the help of his relative to temporarily give BVM ventilation while EMT accessed IV line and also assessed vital signs which were as follows: SpO2 60%, Respiration Rate 06 breaths/min, Pulse Rate 18 beats/min, Pupils were constricted, BP not recordable and RBS 70 mg/dl. EMT immediately contacted Emergency Response Center Physician - Dr. Khemchand Parmar and Dr. Roopchand Ramani and as per their advice; EMT continued BVM ventilation and administered

Inj. Atropine loading dose, Inj. Adrenaline, IV Normal Saline 500 ml and D25% 100 ml. EMT also continuously reassured the patient's relatives as they were very distressed due to this incident.

Patient's condition at the time of handing over:

After implementing all necessary interventions and with continuous monitoring the patient was shifted to Pramukh Hospital, Bodeli after travelling for a distance of 27 km. At the time of handing over to the hospital, the patient's condition had improved.

Reflection of the patient or patient's relative:

The relatives appreciated the care given by EMT and Pilot which ultimately saved the patient's life.

**REFLECTION BY EMT : REKHA MASHURBHA KHANT**

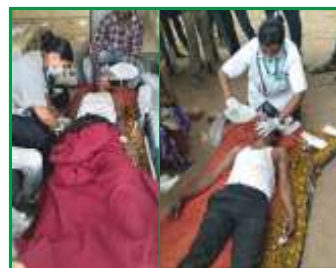"I am very happy and grateful as our case has been selected as savior. We worked very hard and put in all the efforts to save the life of the victim in distress. I also thank my Pilot for supporting me in this life saving mission as our team work definitely helped us in managing this challenging case."

REFLECTION BY PILOT: RATHVA SUBHASHBHAI AMARSINGBHAI

"I feel very proud and am unable to express my feelings with words for being selected as a Savior for the first time. I was eagerly waiting since long for our hard work to be appreciated with a Savior Award. This encourages me to work with more zest and more confidence. I feel very blessed to be associated with EMRI GHS."

**CASE DETAILS****PATIENT RECEIVING PRE-HOSPITAL CARE IN 108 AMBULANCE**

AMBULANCE LOCATION : TEJGADH
 CASE ID : 20250500181939
 DATE : 24/05/2025
 CALL TIME : 10:41 HRS
 ERCP : Dr. KHEMCHAND PARMAR
 Dr. ROOPCHAND RAMANI
 RECEIVING HOSPITAL : PRAMUKH HOSPITAL, BODELI



A CASE OF RTA

MAY 2025

Details of the incident:

On 29th April 2025 at 21:02 hrs Emergency Response Center (ERC) received a call from a good Samaritan from Dhoopadal circle, Ghataprabha main road, who was very frightened and requested for an ambulance urgently, on asking about case details our Emergency Response Officer (ERO) that the victim was a 23 years old Male victim, met with an Two wheeler accident which was a rear right lateral collision between the two wheeler & an auto. The nearest available ambulance was Gokak TLH location.. The case was immediately assigned to ambulance with EMT Mr. Appanna and Pilot Mr.Shankar on duty and they reached the victim location which was 14 km's away within 16 minutes of duration.

Diagnosis or condition:

When the 108-crew arrived at the scene EMT found that he was a 23 year old had severe Head injury with multiple limb lacerated injuries & was

unconscious. It was very challenging for the crew to handle such victim & anxious crowd who had witnessed the breath taking event. The incident was handled by 108 crew in calm & composed professional way while dealing with the victim. Parents of the victim were provided with assurance of speedy recovery of their injured young victim.

Pre-hospital management:

Without delaying EMT & Pilot started shifting the critically injured young victim by means of scoop & simultaneously wounds were treated which included an lacerated wound at right side of the frontal and temporal region, and irregular laceration with severe bleeding were treated wound care was done en route & shifted to Ganga hospital, Gokak. Vitals were recorded Respiratory rate 16 breaths/min, pulse 96beats/min, BP 150/90 mm of Hg, O2 saturation 90%, and Pupils are equally reacting to light. As it was difficult to shift the victim .

Mean while ERCP Dr. Harsha was briefly described the event., Oxygen 6 liters/minute administered, C-collar applied, supine position maintained and IV line secured.

Patient condition at the time of handing over:

Hospital doctors appreciated EMT & Pilot for their presence of mind and the accurate pre hospital management which was given to the victim on scene & in the ambulance before reaching to the hospital. The victim was immediately attended by a Team of Doctors for further evaluation of the victim condition.

Reflection of the patient or patient relative:

Victim's parents & relatives & few of the on lookers showered blessing and showed gratitude towards our ambulance team. Condition of the victim was stable during 48 hour follow up call. The Victims was shifted to the higher facility center for further care.



REFLECTION BY EMT : APPANNA

"It was very challenging case for me and I felt very much satisfied after shifting the victim to the hospital within golden hour. It gives tremendous pleasure to serve people when they are in need of our help & support. I am thankful to EMRI GHS for giving me an opportunity to save the life of a needy. Honesty & integrity are the best essence of satisfied life which I felt after handing over the young life safely. It was a great satisfied feeling to my Soule."

REFLECTION BY PILOT : SHANKAR

"I am happy because I took part in Pre Hospital Care & I was able to shift the patient on time to hospital which made the work of doctors and other staff to treat effectively and I would like to say thanks to EMRI GHS for giving me an opportunity to work as a Pilot in 108 Ambulance to serve the community."



CASE DETAILS

AMBULANCE LOCATION : GOKAK TLH
 CASE ID : 1426313
 DATE : 29/04/2025
 CALL TIME : 21:02 HRS
 ERCP : Dr. HARSHA
 RECEIVING HOSPITAL : GANGA HOSPITAL, GOKAK.

PATIENT RECEIVING PRE-HOSPITAL CARE IN 108 AMBULANCE



MAY 2025

A CASE OF PRE-TERM DELIVERY

Details of the incident:

Aroor PHC ambulance was dispatched to respond to a call regarding a 6month pregnant lady experiencing severe abdominal pain (Pre-term Labour pain). The incident occurred in a residential area at Aroor, Alappuzha approximately 12:46 hrs the ambulance reached at the scene within 7minutes of receiving the call.

Diagnosis or condition:

The EMT quickly assessed the patient's condition (G-3 P-1 L-1 D-0 A-1), based on the uterine contraction frequency and presentation of crowning stage the EMT confirmed that victim is at the event of pre-term Labour.

Pre-hospital management:

Patient was in the home and EMT has monitored the vitals. The saturation

was 98%, Blood Pressure 140/90mmhg, Pulse Rate 88b/m, and the Respiration was 16bts/m. uterine contraction which is lasting for 50 to 70 seconds in 4min. within 8 minutes the baby's head emerge and conducted the delivery at 13:05:34. The baby's weight was 1.3kg, so confirmed as premature baby, immediately clamped and cut the code. The APGAR score were 4. So started neonatal resuscitation and no changes noticed, given care to the mother along with. The baby and mother was immediately shifted to Lakeshore Hospital, Ernakulam

Patient condition at the time of handing over:

After implementing the necessary interventions and continuous monitoring the patient, the EMT observed slight improvement in the baby's condition with NNR, and the

patient was apparently better symptomatically. The EMT ensured that the Baby and Mother was secured on the ambulance and given care according to that. EMT prepared for a smooth handover to the hospital staff upon arrival.

Reflection of the patient or patient relative:

Patient family member expressed gratitude for the EMT's prompt response and effective management of the breathing and airway management. They appreciated the EMT's professionalism, good action to the emergency, and the reassurance provided during a distressing situation. Family members acknowledged the importance of the swift actions taken by the EMT, which contributed to the positive outcome and alleviated their concerns during the ambulance journey.

**REFLECTION BY EMT : MARY**

"It was a really challenging situation as it was a case of premature birth, but due to proper training and knowledge I could manage the situation properly and was able to give necessary pre hospital care to the mother and the newborn."

REFLECTION BY PILOT : SIVANANDAN

"I felt really grateful for being able to help the patient in such a critical situation and did shift the patient safely and quickly to the hospital. Thanking my organization for giving me such great opportunities."

**CASE DETAILS**

AMBULANCE LOCATION : AROOR PHC
CASE ID : 20250500050583
DATE : 16/05/2025
CALL TIME : 12:46 HRS
ERCP : Dr. ANAKHA SAJEEV
RECEIVING HOSPITAL : LAKESHORE HOSPITAL, ERNAKULAM



A CASE OF ELECTROCUTION

MAY 2025

Details of the incident:

On May 25, at 12:55 hrs, a daily wage worker Mr. Suraj was severely injured at a cement red mix concrete site of Thej Kunta of Nalgonda District of Telangana, after a high-voltage electrical wire fell on him. The man was rendered semiconscious and suffered extensive, deep burns to his stomach and both legs. Local residents promptly called the 108 emergency service.

Diagnosis or Condition:

In the crucial moments following the call, our 108 Ambulance team provided vital pre-arrival instructions, advising the caller to move the victim to a safe location and position him laterally. Upon arriving, the EMT and Pilot done the

Rapid Trauma Assessment and found that the victim Mr. Suraj aged 60 years, had severe electrocution burns to his both lower extremities below knee joints and small of upper abdomen, quickly and safely transferred the semiconscious patient into the ambulance.

Pre-Hospital Care or Management:

EMT Mr. Saidulu immediately initiated the High-flow oxygen and upon rapid trauma assessment was he checked for internal injuries and Baseline vitals recorded and found to be normal. The EMT then consulted with a ERCP Dr. Saradhi for to confirm the treatment plan. Based on the doctor's advice, Normal Saline IV fluids were administered to address shock and

hydration, and wound care with sterile wet dressing pads was provided for the severe electrocuted burns areas. Throughout the emergency transport, the EMT continuously monitored the patient's vitals and shifted the Government Area Hospital of Miryalaugda of Nalgonda District.

Reflection of the Patient or Patient relative / villagers and Hospital staff:

The victim later expressed gratitude for the 108 staff. The victim stated that their timely and appropriate treatment saved his life. He acknowledged that the 108 staff helped both him and his family by ensuring his survival.



REFLECTION BY EMT : SAIDULU

"Responding to the high-voltage electrical incident on May 25th was a high-stakes situation from the start. My initial advice over the phone to the caller – to ensure the victim's safety and position him laterally – was crucial, as ensuring the scene is safe is the first step in treating electrical injuries. After examination, consulting with the ERCP doctor and then implementing the IV fluids and wound care according to the protocol underscored the team effort involved in saving a life. Hearing the patient later express that our actions saved him and helped his family is the most profound reward for doing what we do."

REFLECTION BY PILOT : LINGAIAH

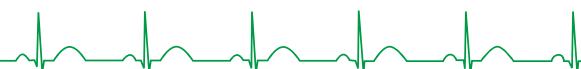"The ambulance pilot's primary concern during the high-voltage electrical accident on May 25th was speed and safety. While the EMT focused on patient care, the pilot focused on maintaining a smooth and swift transport to the hospital. The patient's thanks later emphasised that the combined efforts of the team were pivotal in saving a life and keeping his family intact."



CASE DETAILS

PATIENT RECEIVING PRE-HOSPITAL CARE IN 108 AMBULANCE & RECOVERY

AMBULANCE LOCATION : VEMULAPALLY
 CASE ID : 536194707
 DATE : 25/05/2025
 CALL TIME : 12:55 HRS
 ERCP : Dr. SARADHI
 RECEIVING HOSPITAL : GOVERNMENT AREA HOSPITAL,
 MIRYALAGUDA.



Details of the incident:

When Sarojini Devi, 25, from Shahpur village, Behajam Block, experienced labor pains, her family contacted the 108 ambulance service. Ambulance UP32BG9156, manned by EMT Viresh Kumar and pilot Vijay Yadav, swiftly transported her to Behajam Community Health Center where she successfully delivered her second child. Unfortunately, shortly after birth, the newborn developed hypoxia and severe respiratory distress, causing unconsciousness. Recognizing the urgency, the child was immediately referred to District Women's Hospital, Lakhimpur Kheri. During transit, the child's condition worsened, prompting EMT Viresh Kumar to contact Dr. Rastogi in Lucknow for guidance. Dr. Rastogi advised CPR and oxygen therapy, which Viresh Kumar and Vijay Yadav initiated en route. Through their dedicated efforts, the child's condition stabilized, and they safely transferred him to Lakhimpur Women's Hospital.

Diagnosis or condition:

EMT Viresh Kumar and pilot Vijay Yadav

promptly initiated the primary assessment and triage upon arrival. The newborn was found in critical condition, exhibiting hypoxia and severe respiratory distress, leading to unconsciousness. Recognizing the urgency, the team immediately commenced neonatal resuscitation to stabilize the patient.

Pre-hospital management:

The 108 ambulance promptly arrived at the scene, and in adherence to standard emergency medical protocols, an initial assessment was conducted. The patient was carefully and safely transferred into the ambulance. The Emergency Medical Technician (EMT) recorded baseline vital signs: pulse rate of 37 bpm, body temperature 99.1°F, and respiratory rate 21 breaths per minute, and SpO₂ at 48%. Observing signs of hypoxia and severe respiratory distress leading to poor perfusion, the EMT promptly initiated Cardio pulmonary Resuscitation. After 2 minutes of chest compression and rescue breath administration patient was assessed again, Vital were improved with PR 84 /minute and SPO2 94%,

Following initial stabilization, oxygen therapy was continued using an AMBU bag. With the guidance from ERCP Dr. Rastogi, the patient was transported without delay and safely handed over to the medical team at District Women's Hospital, Lakhimpur, for further definitive care.

Patient condition at the time of handing over:

Upon arrival at the hospital, the patient's condition had improved, vital signs: pulse rate of 85 bpm, and SpO₂ at 94%.

Reflection of the patient or patient's relative:

The patient was safely transported to District Hospital Lakhimpur Women's Hospital. This quick and efficient response ultimately saved the patient's life.

This arrived on time and took the patient to the hospital on time, which saved the life of their patient. We thank the ambulance staff and the government.



REFLECTION BY EMT : VEERESH KUMAR

"Baby was in critical condition, I have provided a pre hospital care with guidance of ERCP and I feel very blessed for being an Emergency Medical Technician in saving lives."

REFLECTION BY PILOT : VIJAY KUMAR

"I would like to express my sincere gratitude to the management for providing this opportunity to contribute towards saving precious lives in a timely manner."



CASE DETAILS

AMBULANCE LOCATION : CHC- PHARDHAN
 CASE ID : 505266
 DATE : 16/5/2025
 CALL TIME : 11:00 HRS
 ERCP : Dr. RASTOGI
 RECEIVING HOSPITAL : DISTRICT HOSPITAL

LAKHIMPUR WOMEN'S HOSPITAL
 DISTRICT- LAKHIMPUR KHERI

PATIENTS RECEIVING PRE-HOSPITAL CARE IN 108 AMBULANCE & MEDIA CLIP



JUNE - 2025

JUNE 2025

A CASE OF COMPLICATED DELIVERY

Details of the incident:

On 17th June 2025, our Santalpur location team received a call from staff nurse of CHC Santalpur for Ms. Rajiben Ahir who was a full term multigravida with intense labor pains. EMT Sudhirdan Gadhavi requested staff nurse to keep her medical records ready for seamless handover takeover.

Diagnosis or condition:

On arrival at scene, staff nurse informed EMT that mother had intense labor pains with leaking of amniotic fluid and that baby was in breech presentation. EMT contacted ERCP Dr Yashkumar Patel for approval as per protocol and as per his advice, EMT immediately transferred mother into the ambulance with the help of Pilot Dilipkumar Rathod and relatives.

Pre-hospital management:

In the ambulance, EMT accessed IV line in the mother, started oxygen and continued to observe mother for imminent signs of delivery. After travelling for 6 -7 km, EMT noticed baby's buttocks in vagina and so he made all necessary preparations for

assistance of breech delivery, turned on halogen lamp for warming and requested Pilot to park ambulance in a safe place. EMT started assisting breech delivery by applying all standard maneuvers. EMT observed that baby's head was stuck so he applied Mauriceau-Smellie-Veit (MSV) maneuver to deliver the head successfully. After delivery of baby, EMT found that baby didn't cry and was complete cyanosed. EMT immediately suctioned her airway and gave proper routine care. After that, EMT started Cardio Pulmonary Resuscitation with Bag Valve Mask ventilation in neutral position as baby's APGAR was 0. EMT continued CPR with BVM till the baby's heart rate increased beyond 60 beats/min. Then, EMT continued BVM every 30 seconds until baby's heart rate, breathing & SpO2 became normal. EMT contacted ERCP Dr. Khemchand Parmar for online medical direction and as per his advice EMT continued oxygenation through Blow by Method. EMT assisted in delivery of placenta & administered Inj. Oxytocin 10 IU and IV RL 500 ml to the mother as per

ERCP advice. EMT assessed vital signs of mother which were as follows: Respiration Rate 14 breaths/min, Pulse Rate 78 bpm, SpO2 98% and Blood Pressure 120/72 mm of Hg. Baby's vital signs had improved which were as follows: Respiration Rate 36 breaths/min, Pulse Rate 122 beats/min & SpO2 92%.

Patient's condition at the time of handing over:

After implementing all necessary interventions and with continuous monitoring mother and baby were shifted to CHC Varahi after travelling for a distance of approximately 30 km. At the time of handing over, both the mother and baby were stable.

Reflection of the patient or patient's relative:

The relatives tremendously appreciated the care given by EMT and Pilot which eventually saved mother and baby's lives and were thankful to the 108 ambulance services.

**REFLECTION BY EMT : SUDHIRDAN GADHAVI**

"I am extremely happy to have been selected as the Savior for the first time. I handled this case with the knowledge and skills attained during my training. Receiving savior award has given me happiness and motivation to continue working hard. I really thank our organization for giving me an opportunity to serve. I also thank my Pilot Dilipkumar Rathod for helping me in this life saving mission."

REFLECTION BY PILOT : DILIPKUMAR RATHOD

"I am grateful, as our case has been selected as the savior of the month. In this case, I helped EMT Sudhirdan Gadhavi in providing care to both Newborn and Mother. I thank all those who have given me this opportunity for saving lives and serving people. This really gives me lots of satisfaction."

**CASE DETAILS****PATIENTS RECEIVING PRE-HOSPITAL CARE IN 108 AMBULANCE**

AMBULANCE LOCATION : SANTALPUR
CASE ID : 20250600131362
DATE : 17/06/2025
CALL TIME : 12:19 HRS
ERCP : Dr. YASH AND Dr. PARMAR
RECEIVING HOSPITAL : CHC VARAHI



A CASE OF RTA

JUNE 2025

Details of the incident:

On 25th Jun 2025, a Road Traffic Accident occurred near National Highway. Crowd gathered and at 1.40 hrs, called 108, for help and save the life of 38 years old victim. Receiving the case ERO assigned the case to Lahoal Location of Dibrugarh District. Taking all the accurate information and status of the victim, the Medical Response Team comprising EMT Hariprasad Puri and Pilot Dipjyoti Borah reached the scene within short time.

Diagnosis or condition:

Reaching the scene, they ensure of the scene safety and shifted the victim Mr. Karim Ali, inside the Ambulance. EMT Mr. Puri on his rapid trauma survey and initial assessment observed that the victim

was bleeding extensively from the lacerated part on his forehead with right leg injury with bleeding and moderate swelling from injured area. Victim was in critical condition. Applying pressure bandage EMT controlled the bleeding, preventing the victim from going to shock. The victim was already in panic and agony.

Pre-Hospital management:

At scene Vitals were monitored by EMT and recorded the vitals as, BP-130/80 mmHg, PR-88 bpm, RR-18/minutes, SPO2-98. EMT placed the patient in a supain position and took ERCP advice from Dr. Anupam Borgohain. According to ERCP advice, proper dressing was done with Cotton and Povidone Solution on the injury areas. Re-assurance by

the EMT, helped the victim to recover from his mental and physical distress.

Patient condition at the time of handing over:

After providing the Pre-hospital care, Enroute EMT kept constant monitoring on the patient. Enroute to the hospital, vitals were recorded as BP-130/85 mmHg, PR-78 bpm, RR-17 bpm, SPO2-99 and he was handed over to Assam Medical College and Hospital.

Reflection of the patient or patient relative:

Victim was in critical condition. His family members are pleased by the efforts of the EMT. The effort of the pilot was exceptional as he quickly and safely drove to scene and hospital.



REFLECTION BY EMT : HARIPRASAD PURI

“Working as EMS Health care provider, it has been always thrilling and knowledge acquiring experience thorough out the process of saving lives. RTA are the most common cases that we deal with. Still every RTA are different and equally important for me. As we receive the call from ERO, we proactively make our pre-arrival preparation accordingly the type of Emergency. The case that I handled gave me a great satisfaction ensuring and giving them a hope of endeavor.”

REFLECTION BY PILOT : DIPJYOTI BORAH

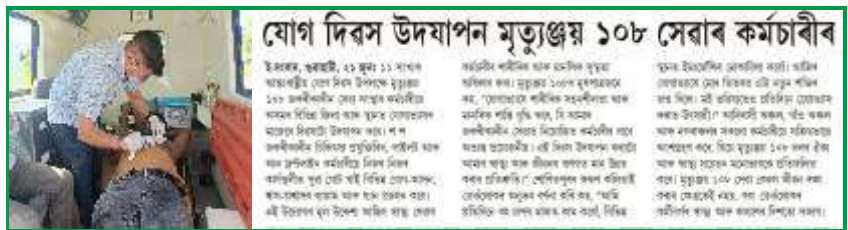“Following the safer side of driving skills, I always follow the traffic rules and try to avoid all kind of hurdle or obstruction that may lead to the delay on the arrival or reaching Hospital. Thanks to GVK EMRI GHS for every aspect and thrive that always keeps keen interest on serving society and saving lives.”



CASE DETAILS

PATIENT RECEIVING PRE-HOSPITAL CARE IN 108 AMBULANCE & MEDIA CLIPPING

AMBULANCE LOCATION : LAHOAL
 CASE ID : 20250600142780
 DATE : 25/06/2025
 CALL TIME : 1:40 HRS
 ERCP : Dr. ANUPAM
 RECEIVING HOSPITAL : ASSAM MEDICAL COLLEGE & HOSPITAL



JUNE 2025

A CASE OF NORMAL DELIVERY

Details of the incident:

On 4th June 2025 at 10:09 hrs, Aldona ambulance, received a call from ERC stating that there was a pregnancy case of signs of delivery. Patient was a 20-year-old female. After taking scene details, EMT and Pilot rushed to the scene with the relevant equipments to provide necessary Pre-hospital care. Ensuring scene safety and maintaining BSI precautions, our team reached on the scene.

Diagnosis or condition:

After assessing scene safety, EMT and Pilot approached patient. patient was conscious. EMT quickly

began patient examination. Patient was already in crowning stage. EMT prepared for delivery with the help of Pilot. Immediately ERCPC conference was taken by EMT. Perineal support was given. Healthy newborn was delivered. Routine newborn care was provided including suctioning, warming, drying, umbilical cord cut and checking APGAR score. EMT then injected IM inj. Oxytocin 10 units to mother. IV fluid RL was administered to the patient.

Pre-hospital management:

Without wasting time, EMT recorded vitals. Vital signs were as follows: Baby APGAR:10, Mother

vitals were recorded as: - BP: 110/80 mm of Hg, Pulse:82 bpm, RBSL:166 mg/dl. External uterine massage was provided to mother.

Patient condition at the time of handing over:

After implementing the necessary interventions and continuously monitoring the mother and newborn, ambulance reached the destination hospital. Patient was handed over in the casualty of PHC Aldona.

Reflection of the patient:

Thank you! EMRI Green Health Services, You are doing a great job. God bless you!



REFLECTION BY EMT : MADHURA OMAJI KAMBLE

“On the scene, as per the information of family members about the pregnant woman's position, we thought that she would not progress further and deliver in the ambulance. As it was a natural process, the delivery progressed, and we conducted the delivery very carefully, and newborn care was provided as per protocols. The Hospital personnel appreciated us a lot, for which we are very proud.”

REFLECTION BY PILOT : PADMANAB BALLAJI MAHMALALIEA

“Victim family members and the Hospital staff appreciated our services for good Pre-Hospital Care praised our sincere efforts in handling such a precious pregnancy case”



CASE DETAILS

PATIENT RECEIVING PRE-HOSPITAL CARE IN 108 AMBULANCE

AMBULANCE LOCATION : ALDONA PHC, NORTH GOA
 CASE ID : 20250600002626
 DATE : 04/06/2025
 CALL TIME : 10:09 HRS
 ERCPC : Dr. RAJAT
 RECEIVING HOSPITAL : ASILO HOSPITAL



A CASE OF RTA

JUNE 2025

Details of the incident:

On 28th May 2025 at 7:15 hrs, Emergency Response Center (ERC) received a call from traffic police near RMM Eco space, Bellandur ring road, A 65 year old person met with an two wheeler accident which was, very frightened and requested for an ambulance urgently, on asking about case details our Emergency Response Officer (ERO). The victim riding Two wheeler hit by the Canter vehicle. The victim had an right sided below knee complete fracture which was severely bleeding and right shoulder fracture. The nearest available ambulance was HSR Layout location which had completed a case and had made a release call (R Call) to ERC stating that they were ready to take the next case. The case was immediately assigned to ambulance with EMT Mr. Basavaraj and Pilot Mr. Hanumanth on duty and they reached the victim location which was 4 km's away within 10 minutes of duration.

Diagnosis or condition:

When the 108-crew arrived at the scene EMT found that he was a 65 year old &

was severely injured with Right lower leg and shoulder fracture & was conscious. It was very challenging for the crew to handle such victim & anxious crowd who had witnessed the breath taking event. The incident was handled by 108 crew in a calm & composed professional way while dealing with the victim. Parents of the victim were provided with assurance of speedy recovery of their injured.

Pre-hospital management:

Without delaying EMT & Pilot started shifting the critically injured young victim by means of SMRD & simultaneously splint were applied to the lower leg fracture and above knee Tourniquet applied to control severe bleeding. For shoulder fracture sling and swath done for immobilization and dressing done and shifted to the nearest varalaxmi hospital, HSR Layout, Bengaluru. Vitals were recorded Pulse – 102beats/min, respiratory rate 24 breaths/min, BP- 100/70 mm of hg, and O2 saturation 92%. Mean while ERCP Dr. Harsha was briefly described the event.

IV fluids started, oxygen 6 liters/minute administered, C-collar applied, semi fowler's position maintained.

Patient condition at the time of handing over:

Hospital doctors appreciated EMT & Pilot for their presence of mind and the accurate pre hospital management which was given to the victim on scene & in the ambulance before reaching to the hospital. The victim was immediately attended by a Team of Doctors for further evaluation of the victim condition.

Reflection of the patient or patient relative:

Victim's parents & relatives & few of the on lookers showered blessing and showed gratitude towards our ambulance team. Condition of the victim was stable during 48 hour follow up call. The Victims was shifted to the higher facility center for further surgical care.



REFLECTION BY EMT : BASAVARAJ

"It was very challenging case for me and I felt very much satisfied after shifting the victim to the hospital within golden hour. It gives tremendous pleasure to serve people when they are in need of our help & support. I am thankful to EMRI GHS for giving me an opportunity to save the life of a needy. Honesty & integrity are the best essence of satisfied life which I felt after handing over the young life safely. It was a great satisfied feeling to my Soule."

REFLECTION BY PILOT : HANUMANTH

"I am happy because I took part in Pre Hospital Care & I was able to shift the patient on time to hospital which made the work of doctors and other staff to treat effectively and I would like to say thanks to EMRI GHS for giving me an opportunity to work as a Pilot in 108 Ambulance to serve the community."



CASE DETAILS

PATIENT RECEIVING PRE-HOSPITAL CARE IN 108 AMBULANCE & MEDIA CLIPPING

AMBULANCE LOCATION : HSR LAYOUT
 CASE ID : 1298627
 DATE : 28/05/2025
 CALL TIME : 07:15 HRS
 ERCP : Dr. HARSHA
 RECEIVING HOSPITAL : VARALAXMI HOSPITAL BENGALURU



JUNE 2025

A CASE OF FALL FROM HEIGHT

Details of the incident:

Koduvally CHC ambulance was dispatched to respond to a call regarding a lady who was hit by a fallen tree. The incident occurred at Kuttikkattoor at approximately 14:35 hrs. The ambulance reached at the scene within 12 minutes of receiving the call.

Diagnosis or condition:

The EMT quickly assess the condition of the patient, she was conscious and oriented, and shows generalized weakness, respiratory distress and sever pain over the back due to hit by a fallen tree. The EMT suspected for spinal injury (L1 to S4) and pelvis injury and suspected for possible respiratory problems.

Pre-hospital management:

The patient was immediately shifted

into the ambulance with spine board and EMT quickly started to provide pre hospital care such as proper positioning to restrict the movements, PPV to get relief from respiratory issues. Checked the vitals, temperature 98.6F, BP 90/60mm of hg, Pulse 72, RR 22 and Spo2 99% and based on this EMT assessed that the patient is in hypotension. EMT quickly administered Inj. Paracetamol IV 100ml.

Patient's condition at the time of handing over:

After implementing the immediate care and continuously monitoring the patient, the EMT observed slight improvement in the patient condition. Her severity of pain is remained stable. The EMT ensured that the patient was secured on the

ambulance and given emergency care according to that. EMT prepared for smooth hand over to the hospital staff of Govt. Medical College Hospital, Kozhikode.

Reflection of the patient or patient relative:

The patient friends and family expressed gratitude for the EMT's prompt response and effective first aid. They appreciated EMT's and pilot professionalism, good action to the emergency and the reassurance provided during a distressing situation .Bystanders acknowledged about the situation ,current status and the importance of the swift actions taken by the EMT and Pilot ,which contributed to the positive outcome and alleviated their concerns during the ambulance journey.

**REFLECTION BY EMT : KRISHNA NANDA**

" It was a challenging case as the patient had suspected spinal injury, but I had applied my knowledge and provided necessary pre hospital care and shifted her on time. Feeling satisfied that I could handle this patient properly."

REFLECTION BY PILOT : ANEESH

"We felt grateful, that we could provide good pre hospital care and promptly transport the victim carefully to the hospital and save her life."

**CASE DETAILS**

AMBULANCE LOCATION : KODUVALLY CHC
 CASE ID : 20250600005209
 DATE : 02/06/2025
 CALL TIME : 14:35 HRS
 ERCP : Dr. ANAKHA SAJEEV
 RECEIVING HOSPITAL : Govt. MCH KOZHIKODE



A CASE OF FALL FROM HEIGHT

JUNE 2025

Details of the incident:

On 6th June 2025, a Good Samaritan called our Emergency Response Officer and reported about a tragic incident that, 22 years old male who climbed a tree to pluck a raw mangoes and accidentally fall from 100 feet height and stucked in between the rocks. His leg was fully trapped in a confined space and unable to move. The bystander understood that the victim is in dangerous situation and he is in need of medical assistance. Hence, he called 108 call centre and requested ambulance service. Our Response Officer assigned the case to Kaveripattinam location ambulance for the support .

Diagnosis or condition:

Ambulance reached the scene within few minutes and the EMT and PILOT started to rescue the victim with the help of nearby assistance. After a lengthy rescue operation, the victim was

rescued safely. EMT assessed the level of consciousness of the victim and she found that he was conscious and oriented. He had crush injury in left lower leg with profuse bleeding .Victim triaged as very urgent category.

Pre-hospital Management:

The victim was placed in a Supine position, Wound wash given and bleeding was controlled followed by dressing done and splint applied .Victim was loaded into the ambulance safely. Oxygen was administration was maintained with 4 lt/mt. Vital parameters were checked and recorded as HR-120bt/min, RR-18 br/min, BP-110/80mm Hg, Temp-98.4 F, Pupils-PERL and SPO2-99% . 2 large bore 18G IV cannula was inserted.

Enroute, ERCP advice taken and the EMT was instructed to administer IV fluid. Normal saline 500 ml administered. Vital signs were monitored Evry 5 minutes once. The victim was

continously reassessed for any life threatening condition. He safely admitted in Government General Hospital, Kaveripattinam .

Patient's condition at the time of handover:

During admission , the victim was alert , vitals were checked and noted HR-116 bts/min, RR-20 br/min, BP-110/80mmHg, SPO2-100%, Temp-98.4 F and Pupils-PERL. The victim reported severe pain on the injured site at the time of handover.

Reflection of the Patient's relative:

Victim's brother thanked our EMT and Pilot for their hardest effort provided in saving the victim's life and he also actively involved in the rescue technique. Though the scene was unreachable, the EMT and Pilot provided an excellent care for the victim. On 48 hours follow up, the patient found to be under post operative care.



REFLECTION BY EMT : AMBIGA

"It was very challenging to walk the distance of 1 km to reach the victim spot, after providing the necessary pre hospital care, we saved his precious life on time. "

REFLECTION BY PILOT : JAYAVEL

"I feel great to work in the Emergency Ambulance Services, and thanks to the EMT who was well supported to transport this case on time."



CASE DETAILS

INCIDENT & PATIENT RECEIVING PRE-HOSPITAL CARE IN 108 AMBULANCE

AMBULANCE LOCATION : KAVERIPATTINAM GH
 CASE ID : 70316
 DATE : 06/06/2025
 CALL TIME : 15:29 HRS
 ERCP : Dr. BALA
 RECEIVING HOSPITAL : GOVERNMENT GENERAL HOSPITAL,
 KAVERIPATTINAM



Details of the incident:

In the village of Venkateswara Palli in Jangaon district, a 60-year-old man named Mr. Shivaratri Elliah, following a dispute with his wife and family members, Mr. Elliah attempted to hang himself. His family members intervened, pulling him down, but he had already lost consciousness and was exhibiting a frightening, foaming-at-the-mouth symptom. They immediately called for emergency medical assistance.

Diagnosis or Condition:

Upon receiving the emergency call about a 60-year-old man attempting suicide by hanging, the Chilpur ambulance team-comprised of EMT Mr. Mohan and Pilot Mr. Amarnath responded rapidly, arriving on scene in minutes. On Initial assessment EMT Mr. Mohan's immediate evaluation revealed that the victim was unconscious and had a severe neck injury from the hanging rope. Observing a respiratory rate of only 7 breaths per minute indicated a critical state of respiratory distress and oxygen

deprivation. The foaming at the mouth, witnessed by the family, also pointed to cerebral hypoxia and potential airway complications.

Pre-Hospital Care or Management:

A cervical collar was applied instantly to immobilize the victim's neck and protect against potential spinal cord damage caused by the hanging. The unconscious patient was then quickly moved into the ambulance. the EMT began providing high-flow oxygen to address the dangerously low respiratory rate and oxygen levels. A rapid trauma assessment was also performed to identify any additional injuries. EMT Mohan contacted an ERCP Doctor Mounika Madam, via phone to explain the situation. Following the doctor's advice, an IV line was started, and the diuretic injection Lasix was administered to address potential pulmonary edema, a known risk in near-hanging incidents. The patient was then placed in a comfortable position, and his airway was continuously managed and monitored to ensure he could breathe

effectively during transport. The ambulance crew then safely transported him to the MGM Hospital of Warangal District.

Reflection of the Patient or Patient relative / villagers and Hospital staff:

The victim's family, initially fearing the worst, expressed profound gratitude to the 108 ambulance staff. The family member said, "when my father was hanged, we thought there were no father, but just minutes after the phone, ambulance team approached us and rushed us to the hospital with essential care very effectively." They credited the ambulance crew's timely arrival and treatment with saving his life, acknowledging that the 108 service's rapid and effective intervention was the sole reason he is still alive today. This reflection underscores the critical importance of a quick and professional emergency medical response in such high-stakes situations.



REFLECTION BY EMT : MOHAN

"Responding to a suicide attempt is always challenging and sensitive. In the case of Shivaratri Elliah, a 60-year-old man who attempted to hang himself, training focused on immediate patient stabilization and critical care. Consulting with the ERCP doctor while assessing his vitals and injuries confirmed the protocol. he patient's family was distraught, which reinforced the emotional weight of these incidents. The goal is to provide hope to the family. The family's later gratitude made the intense work worthwhile, reminding that rapid and skilled intervention can reverse despair and save a life."

REFLECTION BY PILOT : AMARNATH

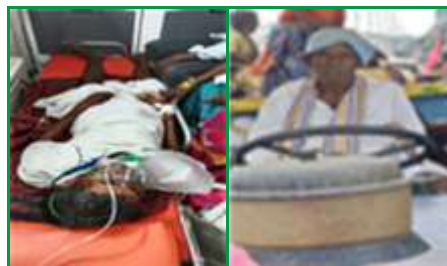"The call for a suicide attempt meant there was no time to spare. The immediate task was to navigate through Venkateswara Palli as swiftly and safely as possible to get EMT Mohan to the scene. The emotional urgency of the call adds pressure, as every second of travel time matters for the patient's prognosis. While Mohan worked on stabilizing the patient, the focus remained on ensuring a smooth and rapid journey to the hospital, constantly monitoring the road while being aware of the critical situation unfolding behind. The family's later reflection that they thought their father was gone, but the team arrived in minutes, underscores the importance of a coordinated and efficient response."



CASE DETAILS

PATIENT RECEIVING PRE-HOSPITAL CARE IN 108 AMBULANCE & RECOVERY PHOTO

AMBULANCE LOCATION : CHILPUR
 CASE ID : 536116796
 DATE : 15/05/2025
 CALL TIME : 17:57 HRS
 ERCP : Dr. MOUNIKA
 RECEIVING HOSPITAL : MGM HOSPITAL, WARANGAL.



A CASE OF TRAIN ACCIDENT

JUNE 2025

Details of the incident:

On Sunday evening, approximately 15:47 hrs, Mr. Pawan Kumar, aged 30, son of Rajendra, resident of Village Saharsa, Post Madhepur, Thana Murliganj, District Madhepura, Bihar, was seated near the gate of the Jansadharan Express train en route from Saharsa to Amritsar. As the train approached Basti railway station to halt, Mr. Kumar suddenly lost his balance. During this, his right foot came into contact with the platform edge, resulting in a severe injury to his right leg and toe. Mr. Pawan Kumar was traveling for employment purposes, accompanied by his neighbor, Mr. Munna. Upon receiving the emergency alert via dial 108, the 108 Ambulance units from Sadar promptly responded to the scene. Pilot Ghanshyam Verma and EMT Ranjit Kumar provided immediate on-site assessment and safely transferred the injured patient onto the ambulance stretcher without delay. The ambulance crew then expedited transport to the District Hospital for further medical management.

Diagnosis or condition:

Pilot Ghanshyam Verma and EMT Ranjit Kumar promptly initiated a primary survey

and triage. The patient, Mr. Pawan Kumar, was found in critical condition with severe bleeding from a deep lower-leg laceration and toe trauma. The team applied direct pressure, dressed and bandaged the wound, and immobilized the limb with an air splint to prevent further damage. After stabilization, the patient was rapidly transported to the District Hospital for definitive care.

Pre-hospital management:

108 Ambulance immediately arrived at the scene, where standard emergency medical protocols were initiated with a quick primary survey and initial assessment. The patient was carefully and safely extricated and secured within the ambulance using spinal precautions. Baseline vital parameters were recorded: pulse 72 bpm, respiratory rate 18 breaths per minute, blood pressure 104/68 mmHg, temperature 98.7°F, and SpO₂ 90% on room air. The patient had a deep wound to the lower leg and a traumatic injury to the toe. EMT immediately initiated lifesaving interventions, including assessment and management of the airway, bleeding control via direct pressure, sterile wound dressing and bandaging. An air splint was applied to immobilize the injured limb, preventing

further soft tissue and vascular compromise, with continuous monitoring of vital parameters. In the teleconsultation, the EMT administered medications as advised: Diclofenac injection for pain relief, Ranitidine for bleeding control, Tranexamic Acid and Normal Saline for fluid resuscitation. Additional critical care measures were implemented as per further guidance from Dr. Satya. The patient was stabilized during transportation and later handed over to District Hospital, Basti for definitive medical management.

Patient condition at the time of handing over:

Upon arrival at the hospital, the patient's condition had improved, as evidenced by stabilized vital signs.

Reflection of the patient or patient's relative:

The patient was safely taken to District Hospital, Basti. This quick and efficient response ultimately saved the patient's life. It arrived on time and took the patient to the hospital on time, saving their patient's life. We thank the ambulance staff and the government.



REFLECTION BY EMT : RANJEET

"It is a matter of great joy and pride for me to receive the Savior Award. This honor has inspired me to work even harder in the emergency service sector. I thank our organization from the bottom of my heart, which gave me this golden opportunity to serve. Also, I express special gratitude to my pilot Ghanshyam verma, who supported me a lot in this life saving mission"

REFLECTION BY PILOT : GHANSHYAM VERMA

"I am grateful that our case was chosen as "Saviours of the Month". In this case, I collaborated with EMT Ranjeet to provide proper care to both the new-born baby and the mother. I thank everyone who gave me this opportunity to participate in this noble work of saving lives and serving people. This experience gives me immense satisfaction and a sense of pride."



CASE DETAILS

AMBULANCE LOCATION : CHC- SADAR
 CASE ID : 234034
 DATE : 08/06/2025
 CALL TIME : 15:47 HRS
 ERCP : Dr. SATYA
 RECEIVING HOSPITAL : DISTRICT HOSPITAL DISTRICT- BASTI

PATIENT RECEIVING PRE-HOSPITAL CARE IN 108 AMBULANCE & MEDIA CLIPPING



Hon'ble Chief Minister of Uttar Pradesh Shri. Yogi Adityanath Launched 2554 New 108 Ambulances on 1st April 2025



EMT Day Celebrations on 2nd April 2025



Hon'ble Chief Minister of Rajasthan Shri. Bhajan Lal Sharma Launched 10 New 108 ALS Ambulances on 7th April 2025



Pilot Day Celebrations on 26th May 2025



International Yoga Day on 21st June 2025



World Environment Day on 5th June 2025





EMRI GREEN HEALTH SERVICES

Devar Yamzal, Medchal Road, Secunderabad - 500 078 Telangana, India.

Tel : + 91 40 2346 2600, 2346 2602 - Fax 2346 2178

www.emri.in