



EMRI GREEN
HEALTH SERVICES
GVK Enterprise

EM CARE

Towards saving lives and bringing hope



CALL 108
EMERGENCY
• MEDICAL • POLICE • FIRE

Spreading... **SMILE**

OPERATING EMERGENCY SERVICES IN 16 STATES
AND 1 UNION TERRITORY IN INDIA.

October, November & December 2023
VOL - 12 ISSUE QUARTER - IV

Partnering States and Union Territories



Towards Saving Lives and Bringing Hope...

Launched on 15th August 2005 in Hyderabad and expanded to 16 States and 1 Union Territory in India



83,493 CALLS ANSWERED EVERY DAY



34,560 EMERGENCIES RESPONDED PER DAY FLEET OF 8,653 AMBULANCES BY TRAVELLING DISTANCE OF 12,71,310 KM PER DAY 11,29,85,318 EMERGENCIES RESPONDED



7,0,27,479 LIVES SAVED SINCE INCEPTION. 6,53,554 DELIVERIES ASSISTED BY EMTS.



Empowering Emergency Care: A Year of Milestones in Indian Healthcare

As we wrap up another eventful year in the field of Emergency Medical Services, it gives us great pleasure to reflect on the remarkable achievements and milestones witnessed at EMRIGHS across various states of India during October, November, and December 2023.

In October 2023, the Health Minister of Gujarat, Shri. Rushikesh Ganesh Bhai Patel, flagged off 50 new 108 ambulances, further bolstering the state's emergency response capabilities. Similarly, in Rajasthan, under the leadership of Hon'ble Chief Minister Shri. Ashok Gehlot, 100 new 108 ambulances, and 100 new 112 Police Mobile Units were launched on 5th October 2023, marking a significant milestone in enhancing public safety and healthcare infrastructure.



The state of Gujarat witnessed commendable progress with the launch of 25 new Mobile Veterinary Units and 47 new 181 Abhayam vans by Hon'ble Chief Minister Shri. Bhupendrabhai Patel on the 10th and 4th of November 2023, respectively. These initiatives underscore the government's holistic approach towards addressing diverse healthcare needs and ensuring the welfare of both humans and animals. Lastly, on 4th November 2023, the EMRI GHS UP Team took a moment to felicitate the best performers from both 108 and 102 ambulance services, recognizing their dedication and exemplary service in saving lives and ensuring the well-being of communities across Uttar Pradesh.

Adding to the pride of our nation, EMRI GHS was honored with the prestigious Asian Covid Warrior Award under the Institutional Category at the 6th Asian EMS Conference held in Tokyo, Japan, on 30th November 2023. This recognition not only acknowledges the relentless efforts of our frontline healthcare warriors but also highlights India's commitment to combating global health crises. Furthermore, Karnataka saw a significant boost in its emergency medical services as Hon'ble Chief Minister Shri. Siddaramaiah inaugurated 262 new 108 ambulances on 30th November 2023. This augmentation of resources reinforces the state's commitment to providing prompt and efficient emergency healthcare to its citizens.

In Uttar Pradesh, under the visionary leadership of Hon'ble Chief Minister Shri. Yogi Adityanath, a significant stride was made towards enhancing emergency medical care with the launch of 674 new 102 ambulances on 5th December 2023. This initiative undoubtedly strengthens the state's emergency response infrastructure and ensures timely assistance to those in need.

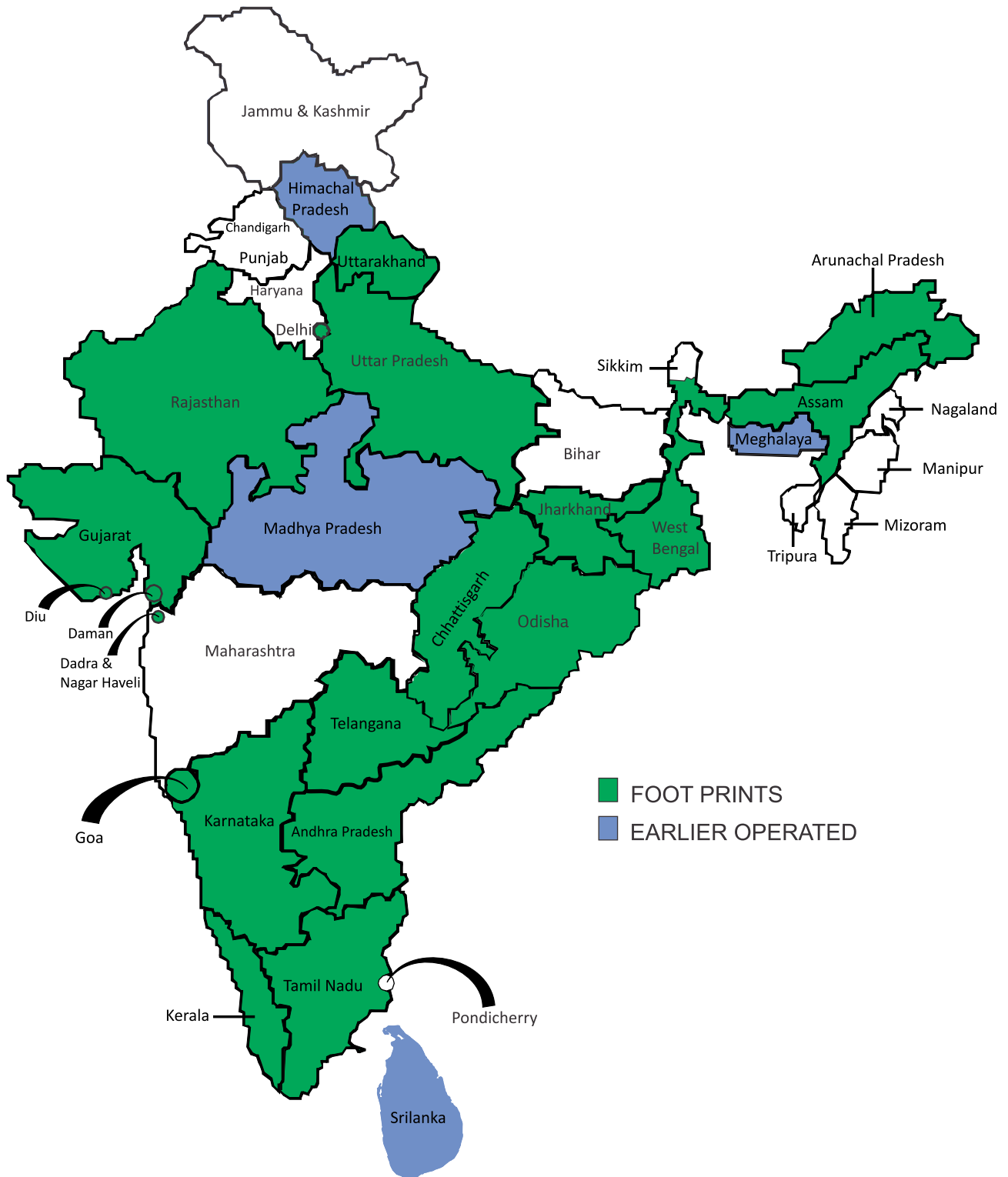
As we conclude this year, let us celebrate these remarkable accomplishments and reaffirm our commitment to advancing emergency medical care for the betterment of society. Together, let us continue to strive towards excellence and make a difference in the lives of those in need.

With best wishes

K. Krishnam Raju

DIRECTOR - EMRI Green Health Services







- 108 Emergency Response Center handles over 250,000 calls daily.
- An impressive 97% of calls are answered within just 2 rings.



Neonatal Ambulance

- Initiated to lower neonatal mortality rates.
- Fully equipped (incubator- ventilator etc.) to facilitate the transfer of newborns between Special Newborn Care Units (SNCU) and Neonatal Intensive Care Units (NICU).



Drop-back Ambulance

- Initiated to reduce infant and maternal mortality rates
- These ambulances are designed to transport pregnant women, mothers and newborn babies from home to hospital and hospital to home in sterile and safe environment



Mobile Medical Unit (MMU)

- Mobile Medical Units(MMU) provide primary health care on wheels.
- Serve medical needs of individuals in remote areas



Boat Ambulance

- Introduced for rapid response to medical emergencies in riverine regions.
- Provide critical healthcare support during floods



Inter Facility Transfer (IFT)

- Primarily used to transit care patients from lower level to higher level hospitals in emergency situations.



Doli-palki

- This innovative approach is designed to carry emergency patients navigate hilly terrains or no road connectivity



- Health helpline services in non-emergency
- This telemedicine service offers information, advice, and counseling



- Implements “Dial 100 Police” service to combat crime and maintain societal peace and safety
- It uses advanced technology to analyze calls, enhance information for rapid response, facilitate follow-up and expedite information sharing to different levels of law enforcement & prompt response.



- "Call 181" - Women Helpline is a dedicated service aimed at assisting women in distress



- Mobile Veterinary Units accessed through 1962 toll free no. provides doorstep point-of-contact- care (POCC) for livestock and stray animals.
- MVUs with Hydraulic lift to carry animals to veterinary facilities in few states

Physical Progress

S. No	Name of the State Government	No of Ambulance	Emergencies Since Inception	Emergencies Attended in December 2023	Deliveries Assisted by EMT since Inception	Deliveries Assisted by EMT in December 2023	Lives saved since Inception	Lives saved in November 2023
1	Telangana	489	84,88,603	46,805	74,686	117	4,98,177	3,630
2	Gujarat	761	1,56,60,772	1,11,389	1,36,882	1,050	14,49,426	10,720
3	Goa	91	7,78,715	6,420	1,148	3	54,083	472
4	Tamil Nadu	1,390	1,56,09,994	1,37,927	67,035	541	12,88,207	14,694
5	Karnataka	715	1,07,67,456	53,246	58,243	133	7,78,284	5,877
6	Assam	802	64,94,272	34,848	52,731	194	2,00,955	1,328
7	Diu Daman & Dadra Nagar Haveli	24	4,16,550	3,219	1,545	19	21,370	273
8	Uttar Pradesh	2,200	3,07,56,084	5,34,450	95,327	22	7,08,917	-
9	Rajasthan	972	51,10,255	45,170	22,438	60	-	-
10	Kerala	316	8,31,232	17,427	95	2	-	-
11	Delhi	240	16,22,113	37,385	-	-	13,98,795	40,209
12	Arunachal Pradesh	110	14,906	1,078	53	5	-	-
13	Jharkhand	543	41,989	16,733	116	54	-	-
Total		8,653	9,65,92,941	10,46,097	5,10,299	2,200	63,98,214	77,203

108 State wise completed projects:

State	Project Tenure	Emergencies Handled	Assisted Deliveries	Lives saved
Meghalaya	Feb'2019-July'2022	2,34,017	2,552	27,439
Himachal Pradesh	Dec'2010 - Jan'2022	15,03,762	12,978	1,39,042
Madhya Pradesh	July'2009 - Sep'2016	37,82,608	27,505	98,251
Kerala	Apr'2014 - Nov'2015	73,143	34	-
Andhra Pradesh	Aug'2015-Dec'2017	72,66,356	70,531	2,72,891
Uttarakhand	May'2008-Apr'2019	13,87,711	15,075	33,458
Chhattisgarh	Jan'2011-Nov'2019	20,55,075	14,669	58,184
Total		1,60,68,655	1,40,792	6,01,826

Janani Shishu Suraksha Karyakram (Mother & Child)

S. No	Name of the State Government	No of Janani Ambulance as on December 2023	Janani Beneficiaries Since Inception	Janani Beneficiaries December 2023
1	Gujarat	414	1,04,33,127	1,37,913
2	Telangana	300	62,32,465	76,626
3	Uttar Pradesh	2,270	7,62,64,955	14,15,033
4	Goa	4	9,113	128
5	West Bengal	950	40,32,567	69,160
6	Tamilnadu	88	16,80,594	18,958
Total		4,026	9,86,52,821	17,17,818
Per Day Calculation		55,413 Dispatches / Day		

JSSK State wise completed projects:

State	Project Tenure	Emergencies Handled
Himachal Pradesh	Nov'2014 - Jan'2022	3,02,336
Assam	Jan'2012 - Dec'2022	24,90,035
Chhattisgarh	Jan'2012 - Dec'2022	69,38,307





108 Saviour of EMRI GHS - INDIA

October 2023	: GOA TEAM	- A CASE OF ANIMAL ATTACK	08
November 2023	: GUJARAT TEAM	- A CASE OF SNAKE BITE	16
December 2023	: UTTAR PRADESH TEAM	- A CASE OF RESPIRATORY DISTRESS	24

STATE WISE CASE OF THE MONTH

October	: GOA TEAM	- A CASE OF ANIMAL ATTACK	08
October	: ASSAM TEAM	- A CASE OF RESPIRATORY DISTRESS	09
October	: GUJARAT TEAM	- A CASE OF MCI	10
October	: KARNATAKA TEAM	- A CASE OF NUCHAL CORD DELIVERY IN 108 AMBULANCE	11
October	: KERALA TEAM	- A CASE OF UNCONSCIOUS PATIENT	12
October	: TAMIL NADU TEAM	- A CASE OF HEAD INJURY	13
October	: TELANGANA TEAM	- A CASE OF RTA	14
October	: UTTAR PRADESH TEAM	- A CASE OF PARALYSIS	15
November	: GUJARAT TEAM	- A CASE OF SNAKE BITE	17
November	: ASSAM TEAM	- A CASE OF RESPIRATORY DISTRESS	18
November	: GOA TEAM	- A CASE OF HYPOGLYCEMIA	19
November	: KARNATAKA TEAM	- A CASE OF ASSAULT	20
November	: KERALA TEAM	- A CASE OF AMBULANCE DELIVERY	21
November	: TAMIL NADU TEAM	- A CASE OF FALL	22
November	: TELANGANA TEAM	- A CASE OF SUICIDE	23
November	: UTTAR PRADESH TEAM	- A CASE OF RTA	24
December	: UTTAR PRADESH TEAM	- A CASE OF RESPIRATORY DISTRESS	26
December	: GOA TEAM	- A CASE OF RTA	27
December	: GUJARAT TEAM	- A CASE OF RESPIRATORY DISTRESS	28
December	: KARNATAKA TEAM	- A CASE OF RTA	29
December	: TAMIL NADU TEAM	- A CASE OF CHEST PAIN	30
December	: TELANGANA TEAM	- A CASE OF RTA	31

NOT FOR PROFIT ORGANISATION OPERATING IN PUBLIC PRIVATE PARTNERSHIP MODEL



A CASE OF ANIMAL ATTACK

OCTOBER 2023

Details of the incident:

On October 27, 2023, at 18:19, our ERC received a distress call from Goyche Bhat Velim, reporting an animal attack involving an ox and a lady. The nearest available ambulance, from Cuncolim, promptly responded to the call. After obtaining scene details, the EMT and Pilot rushed to the location equipped with the necessary tools to administer essential pre-hospital care. En route to the scene, the EMT provided instructions to the caller, advising them to apply direct pressure to any external bleeding and refrain from oral intake for the patient, ensuring initial care.

Patient Assessment:

After assessing the scene safety, the EMT and pilot approached the patient. Victim was found semiconscious. The patient was a 75-year-old female EMT who began a quick rapid trauma survey and found that the patient had a deep laceration at the right eye and right

hand. Immediately wound care was given to the patient and external bleeding was controlled. Meanwhile, the EMT consulted ERCP as the patient was critical. ERCP guided the EMT to give wound care with a comfortable position, IV access with IV NS-500 ml, and pain management medications and asked to monitor vitals every 5 minutes.

Pre-hospital management:

Following ERCP recommendations, the injured areas were dressed, and the patient was carefully transferred into the ambulance. Vital signs were recorded continuously which indicated normal values. Continued wound care was provided as per ERCP instructions, with all interventions performed diligently by the EMT.

Patient condition at the time of handing over:

Following the implementation of necessary interventions and continuous

patient monitoring, the EMT observed an improvement in the patient's condition. Reassurance was provided to the patient during transit to the destination hospital. Upon arrival at the New Hospicio casualty, the patient was handed over for further medical attention.

Reflection of the patient:

Expressing gratitude for the timely and effective assistance received, the patient highlighted the invaluable support provided by the ambulance team. Appreciation was extended to the Government of Goa for the presence of such exemplary 108 services, ensuring the safety and well-being of individuals in critical situations.



REFLECTION BY EMT : MAHENDRA MAURYA

I feel happy that I could manage this case following all the prehospital protocols that I had learned in my training. It was also a great time to feel pride after saving a life.

REFLECTION BY PILOT : MANOHAR VELIP

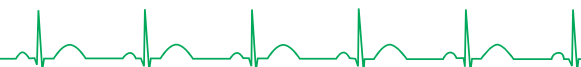It is a great happiness to be a part of life-saving mission . We worked very hard to manage the injured victim.



CASE DETAILS

PATIENT RECEIVING PRE-HOSPITAL CARE IN 108 AMBULANCE

AMBULANCE LOCATION : PHC CUNCOLIM
CASE ID : 20231000019809
DATE : 27-10-2023
CALL TIME : 18:19
ERCP : Dr. NAVJYOT
RECEIVING HOSPITAL : HOSPICIO NEW



Details of the incident:

The husband of Mrs. Ambiya Khatun from Nagaon District dialed 108 for an ambulance. Upon receiving the case, the ERO assigned it to the Dalgaon Ambulance location at 6:38 pm. The team, consisting of EMT Mr. Sankarjit Bora and Pilot Mr. Jintumoni Bora, promptly responded to the call.

Patient Assessment:

Upon arrival at the scene, EMT Sankarjit Bora found a 35-year-old female patient experiencing severe breathing difficulty while lying on a bed. Despite being semi-conscious and responding to painful stimuli, she required immediate attention. The patient was swiftly transferred

to the ambulance for further assessment.

Pre-Hospital management:

During the initial assessment, EMT Sankarjit Bora discovered that the patient was suffering from Chronic Kidney Disease. Seeking advice from ERCP, Dr. Dilip Sharma, the EMT proceeded with Nebulization using Asthalin 2 ampules and administered oxygen as per medical guidance.

Patient condition at the time of handing over:

Vital signs were closely monitored, revealing blood pressure at 180/100 mmHg, pulse rate at 80/min, respiratory rate at 12/min, and SPO2 at 85%. En route to the

hospital, the patient experienced significant relief compared to her initial state. She was handed over to the hospital staff in a stable condition.

Reflection of the patient or patient relative:

Respiratory distress poses a unique challenge for EMTs, and in this instance, EMT Sankarjit Bora demonstrated exemplary professionalism and adherence to ethical standards in managing the case. The patient's family members commended the EMT for his swift actions, acknowledging that his intervention, along with the assistance of the Pilot, potentially saved the patient's life.



REFLECTION BY EMT : SANKARJIT BORA

I was highly delighted when the victim's relative appreciated me and my colleague for providing the treatment and saving his life. Being an EMT, I always tried my best to provide the victim, with maximum care and comfort using my technical skills and experiences.

REFLECTION BY PILOT : JINTUMONI BORA

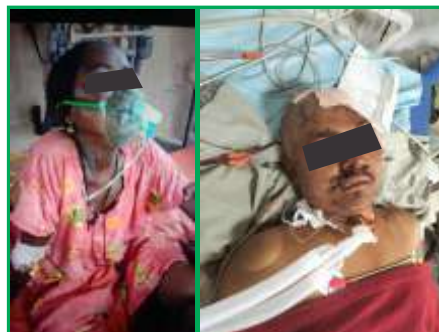I take the opportunity to thank EMRI GHS, NHM, and Govt. of Assam for providing us such a huge platform to use our technical skills to help the needy people of Assam. I never let go of the chance to serve society on duty.



CASE DETAILS

AMBULANCE LOCATION : AIBHETI MPH
CASE ID : 20231000016716
DATE : 03-10-2023
CALL TIME : 11.29 AM
ERCP : DR. DILIP SHARMA
RECEIVING HOSPITAL : GMCH

PATIENT RECEIVING PRE-HOSPITAL CARE IN 108 AMBULANCE



A CASE OF MCI

OCTOBER 2023

Details of the incident:

At 3:39 hrs. on October 21, 2023, the Dudhai Location ambulance responded to a Multi Casualty Incident involving a Road Traffic Accident. One victim sustained serious injuries, while two others had minor abrasions on their upper limbs.

Patient Assessment:

Upon arrival at the scene, the EMT assessed Kishanbhai Dabhi, who had suffered a puncture wound to the frontal part of his head, accompanied by Ear and Nose bleeding, periorbital ecchymosis, and multiple abrasions on his face. The patient was unresponsive and exhibited symptoms of bradypnea, bradycardia, hypoxia, and hypotension.

Pre-hospital management:

The EMT promptly enlisted the assistance of bystanders to control bleeding by applying light pressure to the head wound. Simultaneously,

airway clearance was conducted through suctioning, followed by maintenance using an Oro Pharyngeal Airway. Bag Valve Mask Ventilations were initiated, alongside the application of a spinal motion restriction device with a C-collar. With assistance from the Pilot and bystanders, the patient was carefully transferred into the ambulance. The EMT continued Bag Valve Mask Ventilations with high-flow oxygen in a shock position, establishing two IV lines for fluid administration. Vital signs were monitored, revealing a Respiration Rate of 08 breaths/min, Pulse Rate of 32 beats/min, SpO2 of 78%, dilated and non-reactive bilateral pupils, RBS of 103 mg/dl, and BP of 90/50 mm of Hg. The EMT consulted ERCP Dr. Khemchand Parmar for online medical direction multiple times, subsequently administering Inj. Atropine, Inj. Adrenaline, and IV fluids NS and RL 500 ml as per medical advice.

Patient condition at the time of handing over:

Following the implementation of all necessary interventions and continuous monitoring, the patient was shifted to G K General Hospital, Bhuj which is 25 kms away from the scene. At the time of handover, the patient's condition had shown signs of improvement.

Reflection of the patient or patient's relative:

The relatives expressed appreciation for the care provided by the EMT and Pilot.



REFLECTION BY EMT : VIJAY KAMLIYA

I am extremely happy to be selected as a Savior for the first time. I would like to thank our organization for giving me this opportunity to save lives. This recognition motivates us to work even more passionately. Good teamwork makes miracles!

REFLECTION BY PILOT : MERU BHUVA

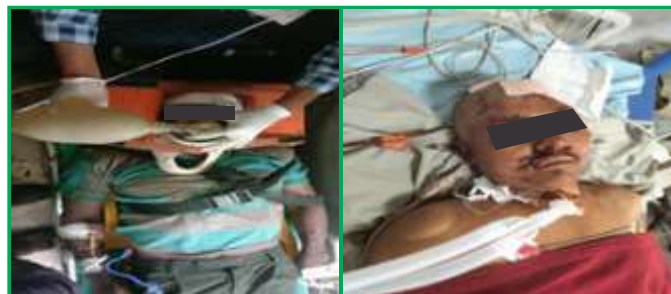I feel very proud and am at a loss for words to describe my feelings for being selected as a Savior for the first time. I am thankful to everyone who considered me to be worthy of participating in this life saving mission. I feel very lucky to be associated with this prestigious organization.



CASE DETAILS

PATIENT RECEIVING PRE-HOSPITAL CARE IN 108 AMBULANCE

AMBULANCE LOCATION : DUDHAI
CASE ID : 20230100284708
DATE : 21/10/2023
CALL TIME : 02:39 HRS
ERCP : Dr. KHEMCHAND PARMAR
RECEIVING HOSPITAL : G K GENERAL HOSPITAL BHUJ,
KUTCH



Details of the incident:

On October 27th, 2023, a distress call was received from PHC Kadugudi, Bangalore district, seeking urgent medical assistance for a 29-year-old pregnant woman experiencing active labor with a nuchal cord. The case was swiftly assigned to the PHC-AGH location ambulance, manned by EMT Vijay and Pilot Nagaragouda.

Patient Assessment:

Upon arrival at the scene, the 108 ambulance crew found the mother in active labor, with her Last Menstrual Period (LMP) recorded as February 14th, 2023, and the Expected Due Date (EDD) as October 27th, 2023. With the assistance of the Pilot and a family member, the mother was carefully transferred into the ambulance. Baseline vitals were recorded, indicating a Pulse of 106 bpm, BP of 120/80 mm of Hg, Respirations at 20 breaths per minute, and SPO2 at 98%.

Pre-hospital management:

While en route to the hospital, the EMT observed that the mother was in the crowning stage, indicating immediate delivery. With swift action, the EMT facilitated the safe delivery, swiftly removing the cord around the baby's neck before the birth. A healthy male baby was born with active crying, and neonatal care protocols were promptly initiated. Following ERCP Dr. Mahima, instructions the placenta was delivered without complications.

Patient condition at the time of handing over:

Following the necessary interventions and continuous monitoring, the patient's condition improved significantly. Vital signs stabilized within normal ranges, and the patient appeared more comfortable. The APGAR score was recorded as 10/10. The EMT initiated medical interventions for the mother, including injection of

Oxytocin and intravenous fluid administration. The patient and newborn were safely handed over to the hospital staff at Vanivilas Hospital, Bangalore.

Reflection of the patient or patient relative:

The patient and their family member expressed heartfelt gratitude for the EMT's prompt response and effective management during the delivery. They commended the EMT's professionalism, calm demeanor, and reassurance provided throughout the distressing situation. Acknowledging the importance of the swift actions taken by the EMT, the patient and family member expressed relief and appreciation for the positive outcome achieved during the ambulance journey.



REFLECTION BY EMT : VIJAY KUMAR

Pre hospital care Management was done. My Pilot Naranagouda supported during the emergency it was a great help in shifting the patient.

REFLECTION BY PILOT : NAGARAGOUA
I am happy to save the precious life & proud to be in EMRI Green Health Services of Karnataka.



CASE DETAILS **MOTHER AND BABY RECEIVING PRE HOSPITAL CARE IN 108 AMBULANCE**

AMBULANCE LOCATION : AGH-PHC, BENGALURU
 CASE ID : 1885608
 DATE : 27-10-2023
 CALL TIME : 15:52PM
 ERCP : :DR. MAHIMA
 RECEIVING HOSPITAL : VANIVILAS HOSPITAL, BANGALURU



A CASE OF UNCONSCIOUS PATIENT

OCTOBER 2023

Details of the incident:

The Mangalapady PHC ambulance was dispatched in response to a call concerning a patient experiencing drowsiness and shortness of breath. The incident occurred in a Hospital area at 03:32 PM, with the ambulance arriving at the scene within 02 minutes of receiving the call.

Patient Assessment:

Upon assessment, the EMT quickly identified signs suggestive of convulsion, a decrease in saturation levels, and symptoms indicative of potential arrest, considering the patient's presentation of drowsiness and shortness of breath. Additionally, the EMT noted the patient's pale appearance, indicating a deteriorating condition that warranted immediate attention.

Pre-hospital management:

The patient was promptly transferred

into the ambulance, where vital signs were monitored. The saturation level was recorded at 88%, blood pressure at 80/50 mmHg, pulse rate at 42 beats per minute, and respiration at 22 breaths per minute. Recognizing the severity of the situation, the EMT initiated pre-hospital care en route. Intravenous fluid therapy with 500ml of Normal saline and Oxygen therapy at a rate of 15 liters per hour with an AMBU Bag were administered. CPR was also initiated to address the worsening condition. The patient was expedited to Govt. General Hospital Kasaragod for further medical attention.

Patient condition at the time of handing over:

Despite the implementation of necessary interventions and continuous monitoring, the patient's condition showed signs of deterioration. Breathing difficulties escalated, and vital signs, including blood pressure,

heart rate, and saturation, declined further, ultimately leading to arrest. The EMT ensured the patient's stability within the ambulance and prepared for a seamless handover to hospital staff upon arrival.

Reflection of the patient or patient relative:

The patient's family expressed gratitude for the EMT's prompt response and effective management of the breathing and airway complications. They commended the EMT's professionalism and swift action during the emergency, providing reassurance in a distressing situation. Acknowledging the crucial role played by the EMT, the family members appreciated the timely interventions that contributed to the positive outcome and alleviated their anxieties during the ambulance journey.



REFLECTION BY EMT : ANUROOP

I am so happy that my case has made it to the National EM care this time. I have been working hard towards it and finally today God has rewarded my efforts.

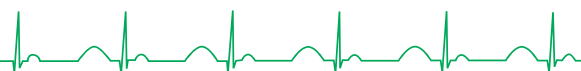REFLECTION BY PILOT : THAHA

In this case, I focussed on my approach to ambulance transportation, ensuring that I drove in a manner conducive to the provision of effective pre-hospital care by the EMT.



CASE DETAILS

AMBULANCE LOCATION : MANGALAPADY PHC
CASE ID : 20231000049885
DATE : 2023-10-13
CALL TIME : 15:32:49
ERCP : DR.
RECEIVING HOSPITAL : MANGALAPADY PHC



Details of the incident:

On October 12, 2023, a compassionate individual reached out to our 108 Emergency Response Centre seeking ambulance support for a 28-year-old male involved in a road traffic accident near Sarakampatti in the Karur district. Without delay, our ERO swiftly directed this case to the Thangampatti location for immediate assistance.

Patient Assessment:

Upon arrival at the scene, the EMT adhered to BSI precautions. During the initial assessment, the victim was discovered in a state of disorientation, displaying severe head injuries in the frontal region, accompanied by bleeding and swelling.

Pre-hospital management:

The victim was immobilized and positioned supine. Bleeding was managed with gentle pressure dressing, while high-flow oxygen was provided. Vital signs were monitored and noted as abnormal. An IV line was established for fluid administration. Once stabilized, the victim was transferred into the ambulance. Following the victim's placement in the ambulance, intravenous fluid was administered based on ERCP guidance.

Patient condition at the time of handover:

The EMT continuously reassessed the patient's conscious level and vital signs to monitor for any additional complications. Subsequently, the patient was safely admitted to the Government

General Hospital in Karur for further management.

Reflection of the patient or patient's Relative:

The public expressed their appreciation for the timely services provided by the EMT and Pilot, and the victim conveyed heartfelt gratitude for saving his life. Additionally, the fellow passengers extended their sincere thanks to our 108 services.



REFLECTION BY EMT : MS.THANGAPONNU

On scene the victim was found with severe bleeding I took instant measures to arrest bleeding and saved the victims life

REFLECTION BY PILOT : MR. RAVICHANDRAN

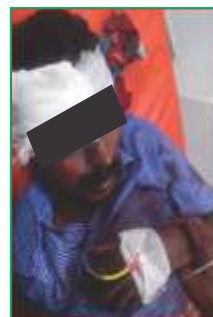I am proud to say that I am Pilot of 108, in this noble profession I am privileged to do social service through this platform



CASE DETAILS

PATIENT RECEIVING PRE-HOSPITAL CARE IN 108 AMBULANCE

AMBULANCE LOCATION : THANGAMPATTI
 CASE ID : 2897870
 ERO : Ms. Gayathri S
 DATE : 12-10-2023
 CALL TIME : 21 :06 HRS
 ERCP : DR. MEERA
 RECEIVING HOSPITAL : Government Medical College Hospital,
 Karur



A CASE OF RTA

Details of the incident:

On 10th October 2023, at 10:10 hrs. Our 108 Thallada Ambulance Team received a call to attend a Road Traffic Accident of Lorry Head-On Collision (Extrication). The incident was reported on the National Highway of Hyderabad and Rajahmundry at the outskirts of Metapalli village, Thallada Mandal Head Quarters of Khammam District. Mr. Umar Mukthar was driving a loaded lorry, at high speed lost control and collided with a roadside big tree. In this incident, this driver sustained serious injuries. The bystanders, who saw the accident called the 108 services to help the injured victim and also informed the Police.

Patient Assessment:

On reaching the scene, EMT Mr. Ramarao, performed rapid scene size up, taking the help of police and other officials who had already reached, to control the mob and establish scene safety. EMT along with Pilot Mr. T Krishna entered the cabin and assessed the victim Mr. Umar Mukthar aged 50, conscious, that both his legs

were completely stuck beneath the dashboard at the steering point and also had multiple abrasions all over the body.

Pre-Hospital Care or Management:

EMT requests Police Personnel for bringing JCB and a welder for process of extrication of the victim. EMT with help of Pilot Mr. T Krishna taken immediate steps of controlling the bleeding of the laceration wound by applying pressure bandage under aseptic conditions, applied C-Collar and then contacted ERCP Dr. Srikanth, explained the situation of the victim in the cabin, he advised IV fluids initiated on the left arm and maintained the vitals carefully, the total extrication process took more than two hours at the scene, after which the victim was carefully lifted and shifted into the ambulance by using of scoop stretcher, provided immobilization, wound care and splinting provided to fractured limbs and high flow oxygen was initiated. The baseline vitals were recorded; BP 90/60 mm of Hg, Pulse rate 96/min and Respiratory rate 21/min. EMT informed about the baseline vitals and as

per the advice ERCP, IV fluids to both arms, Injection Rantac and Injection Tramadol IM given for pain relief.

Patient condition at the Time of Hand over:

Enroute, the EMT Mr. Ramarao did a reassessment of the victim condition and found stable. Along with Police personal, with close monitoring, the victim was shifted to The District General Hospital Khammam for further surgical care and management.

Reflection of the Patient or Patient relative / villagers and Hospital staff:

Our Associates later learnt from follow-up and further recent enquiries. We were further informed by the hospital team that he underwent Orthopedic surgery and his both legs were amputated. After specialized care for some weeks and complete recovery, he was discharged. Hospital staff who were present at the hospital appreciated all the Pre-Hospital Care and services of 108.



REFLECTION BY EMT : NALLAGATLA RAMARAO

On seeing the damage of the vehicle on the scene, it's fortunate that with careful planning of the extrication, we could save the victim after that so much of time and providing timely good Pre-Hospital Care, with help of Pilot Mr. T Krishna, shifted him very carefully into the ambulance and reached the Hospital within a short period. We feel very proud and more confident that we did all the best possible treatment, because of our training in saving such lives.

REFLECTION BY PILOT : THALURI KRISHNA

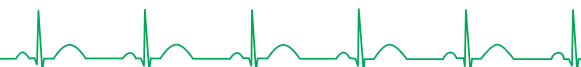It was a very challenging activity to control bleeding by applying bulk dressing and pressure bandage appropriately. We feel proud that we reached out immediately and given timely Pre-Hospital wound care and bleeding control, saved the victim's life.



CASE DETAILS

AMBULANCE LOCATION : THALLADA
 CASE ID : 202301036078672
 DATE : 10/10/2023
 CALL TIME : 10:10
 ERCP : DR. SRIKANTH
 RECEIVING HOSPITAL : DGH - KHAMMAM

INCIDENT PHOTOGRAPH



Details of the incident:

In Unnao District, an incident unfolded involving an individual experiencing a paralysis attack. Initially, the victim was transferred to CHC Nawabganj. However, given the critical nature of the case, the victim was subsequently referred to District Hospital Unnao for further treatment and management.

Patient Assessment:

Upon arrival at the hospital, the attending doctor informed the EMT that the case was suspected to be a stroke requiring brain imaging and specialized care and management.

Pre-hospital management:

Recognizing the critical nature of the case and the importance of time, the EMT promptly initiated appropriate interventions by transferring the patient into the ambulance. Vital

signs were assessed by the EMT, revealing the patient's baseline readings as follows: BP 198/96 mm/Hg, Pulse 112 beats/minute, respiratory rate 14 breaths/minute, and SPO2 at 97%. The ERCP was immediately contacted, and under their medical direction, antihypertensive medication and IV fluid were administered. With the patient continuously monitored and reassured every 5 minutes, transportation proceeded to the destination hospital, District Hospital Unnao.

Patient condition at the time of handing over:

Following the implementation of necessary interventions and continuous monitoring during transit, the patient's condition improved upon arrival at the hospital, with improved vital signs noted.

Reflection of the patient or patient's relative:

The swift response to the emergency is greatly appreciated, as the staff efficiently and effectively cared for the patient. Their prompt actions undoubtedly contributed to saving the patient's life. We extend our heartfelt gratitude to the 108 staff for their exceptional service.



REFLECTION BY EMT : SUDHIR

The doctor referred the patient from KALAVATI CHC Nawabganj to the District Hospital. I promptly transferred the patient to the ambulance and collaborated with ERCP for assistance. I closely monitored the patient's blood pressure and consciousness level throughout the journey, ensuring their safe admission to the district hospital.

REFLECTION BY PILOT : RAHUL

Upon receiving the case assignment, I immediately initiated the ambulance and arrived at the scene. Subsequently, I safely transported the patient to the district hospital, ultimately saving their life.



CASE DETAILS

PATIENT RECEIVING PRE-HOSPITAL CARE IN 108 AMBULANCE

AMBULANCE LOCATION : CHC NAWABGANJ
 CASE ID : 783642
 DATE : 27/10/2023
 CALL TIME : 21:30 HRS
 ERCP : Dr. SAURABH
 RECEIVING HOSPITAL : DIST HOSPITAL UNNAO



NOVEMBER - 2023

Details of the incident:

On November 8, 2023, Sonaben Parmar was bitten by a snake on her right hand around 8 am. Initially, her relatives engaged in some superstitious activities, wasting valuable time. However, when she lost consciousness, they transported her to Danta CHC in a private vehicle. At Danta CHC, the doctor began primary treatment, but her condition deteriorated. Consequently, the CHC doctor promptly called 108 services around 13:32 pm.

Patient Assessment:

Upon arrival at the scene, the EMT found Sonaben unresponsive with bite marks on her finger. She was experiencing breathing difficulty, tachycardia, bradypnea, hypertension, hypoxia, hemoptysis, and dilated pupils.

Pre-hospital management:

The EMT swiftly cleared Sonaben's airway with suction, inserted a Naso Pharyngeal Airway to maintain it, and initiated Bag Valve Mask ventilations. With the assistance of the Pilot and relatives, the patient was carefully transferred into the ambulance. In transit, vital signs were assessed, revealing a respiratory rate of 6 breaths/min, pulse rate of 118 beats/min, blood pressure of 200/110 mmHg, SpO2 of 60%, RBS of 130 mg/dl, and dilated pupils. The EMT requested the Pilot to continue Bag Valve Mask ventilation with high-flow oxygenation while applying splinting on the affected limb. Furthermore, the EMT contacted ERCP Dr. Roopchand Ramani and Dr. Jayant Patel for online medical direction. Following their advice, she continued Bag Valve Mask ventilation with high-flow oxygenation and administered a loading dose of Inj.

ASV in NS and Inj. Hydrocortisone.

Patient condition at the time of handing over:

After implementing all necessary interventions and traveling approximately 38 km with continuous Bag Valve Mask Ventilation and monitoring, the patient was transferred to Civil Hospital, Palanpur. Upon handover, there was some improvement noted in the patient's vital signs

Reflection of the patient or patient relative:

The relatives expressed wholehearted appreciation for the efforts made by the EMT and the Pilot.



REFLECTION BY EMT : YOGITA PATEL

I am deeply grateful and elated that our case has been recognized as a Savior for the first time. However, the true joy comes from saving a patient's life and seeing smiles on the faces of their relatives. I extend my heartfelt thanks to our organization for granting me the opportunity to make a difference in people's lives. Our teamwork was instrumental in managing this critical patient in a challenging snake bite case. Indeed, good teamwork can achieve miracles!

REFLECTION BY PILOT : NAGENDRASINH BARAD

I am filled with immense pride and find it difficult to put into words my feelings about being chosen as a Savior for the first time. I extend my heartfelt gratitude to everyone who deemed me worthy of participating in this life-saving mission. I consider myself incredibly fortunate to be affiliated with the EMRI GHS Organization.



CASE DETAILS

PATIENT RECEIVING PRE-HOSPITAL CARE IN 108 AMBULANCE

AMBULANCE LOCATION : TUNDIYA
 CASE ID : 20230110100893
 DATE : 08/11/2023
 CALL TIME : 13:32 HRS
 ERCP : : Dr. ROOPCHAND RAMANI AND
 Dr. JAYANT PATEL
 RECEIVING HOSPITAL : CIVIL HOSPITAL, PALANPUR,
 BANASKANTHA



A CASE OF RESPIRATORY DISTRESS

NOVEMBER 2023

Details of the incident:

The family member of Mr. Nur Mohammad from South Salmara District contacted 108 ambulances. Upon receiving the case, the Emergency Response Officer (ERO) assigned it to the Fakirganj Ghat Ambulance location at 1:25 pm. The team, consisting of EMT Mr. Abadur and Pilot Mr. Iman Ali Ahmed, promptly rushed to the scene.

Patient Assessment:

Upon arriving at the scene, EMT Abadur observed 52-year-old Mr. Mohammad lying on the bed, expressing complaints of breathing difficulty for the past 7 hours, along with abdominal pain, chest pain, confusion, mobility issues, speech difficulty, dizziness, headache,

hypertension, nausea, tenderness, weakness, and wheezing sounds. Recognizing the severity of his condition and unstable vital signs, EMT Abadur and Pilot promptly transferred the patient to the ambulance.

Pre-Hospital management:

During the initial assessment, the EMT discovered that the patient had a history of high blood pressure spanning several years. Seeking guidance, the EMT consulted with Dr. Dilip Sharma via ERCP and followed the advice provided. Consequently, oxygen was administered to the patient as directed.

Patient condition at the time of handing over:

The EMT continuously monitored the patient's vital signs, recording a blood pressure of 170/110 mmHg, a pulse rate of 106/min, and a respiratory rate of 20/min. During the journey, the patient experienced significant relief compared to earlier.

Reflection of the patient or patient relative:

The patient was experiencing difficulty breathing. The EMTs utilized their skills and expertise to stabilize the patients, administering oxygen and positioning them comfortably. The EMT felt gratified knowing that the pre-hospital care provided brought relief to the patient.



REFLECTION BY EMT : ABADUR

We have noticed that respiratory distress is something we often deal with. However I have learned that giving pre-hospital care before reaching the hospital can help in the patient outcomes.

REFLECTION BY PILOT : IMAN ALI AHMED

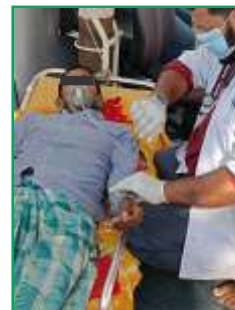
I make an effort to help my EMT in transporting the patient to the nearest appropriate hospital as quickly as possible, ensuring the patient receives timely treatment.



CASE DETAILS

PATIENT RECEIVING PRE-HOSPITAL CARE IN 108 AMBULANCE

AMBULANCE LOCATION : FAKIRGANG GHAT
CASE ID : 20231100157295
DATE : 25-11-2023
CALL TIME : 1.23 PM
ERCP : DR. DILIP SHARMA
RECEIVING HOSPITAL : DHUBRI CIVIL HOSPITAL.



Details of the incident:

At 08:50 am on November 14, 2023, Margo ambulance received a call from ERC reporting an unconscious individual at Colva near Chapel. The EMT and Pilot promptly rushed to the scene. En route, the EMT contacted the caller to provide pre-arrival instructions, advising against giving anything orally. Upon arrival, our team ensured scene safety and implemented BSI precautions.

Patient Assessment:

The EMT and Pilot approached the patient. During the initial assessment, they found a 55-year-old male experiencing breathing difficulties, with a history of diabetes and cardiac disease, and responding to verbal stimuli. The EMT promptly positioned the patient comfortably and initiated high-flow oxygen. With the assistance of the Pilot, the patient was loaded

into the ambulance. Recorded vital signs indicated a blood pressure of 70/50 mmHg, pulse rate of 42, SPO2 of 78%, respiratory rate of 24 breaths/min, and blood sugar level of 28 mg/dl.

Pre-hospital management:

The medical assessment indicated that the patient was experiencing hypoglycemia, hypoxia, bradycardia, tachypnea, and hypotension. The EMT promptly accessed an IV line and contacted ERCP for guidance. Following their advice, the EMT initiated treatment with Dextrose 25% followed by Normal saline, while ensuring the patient received high-flow oxygen in a comfortable position.

Patient condition at the time of handing over:

After implementing the necessary interventions and continuously

monitoring the patient, the EMT observed an improvement in the patient's condition. Providing reassurance to the patient, the ambulance reached the destination hospital. The patient was then handed over at the casualty department of New Hospicio Hospital.

Reflection of the patient:

I am happy that I have given prompt and best pre-hospital care to the patient to the best of my knowledge.



REFLECTION BY EMT : SHITAL TARI

I have provided the best pre-hospital care. When we managed this case, we felt that we had saved the life of the victim.

REFLECTION BY PILOT : RAJENDRA AVATI

I am proud to say that I am a Pilot of 108, in this noble profession I am privileged to do social service through this platform



CASE DETAILS

PATIENT RECEIVING PRE-HOSPITAL CARE IN 108 AMBULANCE

AMBULANCE LOCATION : MARGAO UHC
 CASE ID : 20231100008898
 DATE : 14-11-2023
 CALL TIME : 08.50
 ERCP : DR. KELVIN
 RECEIVING HOSPITAL : HOSPICIO NEW



A CASE OF ASSAULT

NOVEMBER 2023

Details of the incident:

On November 25, 2023, a distress call was received from bystanders who witnessed a 23-year-old male being assaulted by several unknown individuals, presumably due to personal issues. The incident occurred near Suntikoppa road in Kodagu district. 108 services were activated, requesting both Police and medical assistance for the severely injured individual. The case was promptly assigned to the Suntikoppa PHC location ambulance, which was staffed with EMT Lokesh and Pilot Manoj Kumar.

Patient Assessment:

Upon reaching the scene, the 108 crew discovered that the victim had sustained a head injury and multiple lacerations on the upper left side of the body, resulting in severe bleeding. The EMT assessed the patient and determined that he was conscious. With the assistance of the Pilot and bystanders, the victim was carefully shifted into the ambulance. Baseline vitals were recorded, revealing a pulse of 106 bpm, blood pressure of 120/80 mmHg,

respiratory rate of 20 breaths per minute, and SPO2 of 98%

Pre-hospital Management:

The EMT assessed the vitals, noting a blood pressure of 130/70 mmHg, pulse rate of 104 beats per minute, respiratory rate of 20 breaths per minute, and SPO2 of 94%. ERCP Dr. Priyanka was contacted, and pre-hospital care was provided according to her instructions. Pre-hospital Management: Oxygen at 2 liters per minute, Intravenous fluid (IVF RL) at a rate of 20 drops per minute was administered, and Wound care was given, Bleeding control measures were implemented, Injection Tramadol IM 1 ampule was administered, Splinting and bandaging were performed.

Patient condition at the time of handing over:

After implementing the necessary interventions and continuously monitoring the patient, the EMT observed an improvement in the patient's condition. The patient appeared comfortable, and

bleeding was controlled. Vital signs, including blood pressure and heart rate, stabilized within normal ranges. The EMT ensured that the patient was securely positioned on the stretcher and ready for a seamless handover to the hospital staff upon arrival. Subsequently, the patient was transferred to Medicare DH. The doctors at the hospital expressed their appreciation for the efforts of our EMT and Pilot in saving the patient's life.

Reflection of the patient or patient relative:

The patient and their family members expressed heartfelt gratitude for the EMT's prompt response and effective management of the victim. They commended the EMT's professionalism, calm demeanor, and the reassurance provided during a distressing situation. Recognizing the significance of the swift actions taken by the EMT during the ambulance journey, they acknowledged that it played a crucial role in saving the life of a young victim.



REFLECTION BY EMT : LOKESH

It was a case of manhandling with head injury & the victim was conscious but bleeding. Pre hospital care Management was done. My Pilot Manojkumar supported during the emergency. It was a great help in shifting the patient.

REFLECTION BY PILOT : MANOJKUMAR


I am happy to save the precious life & proud to be in EMRI Green Health Services of Karnataka.



CASE DETAILS

PATIENT RECEIVING PRE-HOSPITAL CARE IN 108 AMBULANCE

AMBULANCE LOCATION : SUNTIKOPPA PHC, KODAGU DIST
CASE ID : 1885608
DATE : 25-11-2023
CALL TIME : 17:51PM
ERCP : Dr. PRIYANKA
RECEIVING HOSPITAL : MADIKERI DIST HOSPITAL.



Details of the incident:

The Vadakkanchery CHC ambulance was dispatched to respond to a call regarding a patient experiencing labor pain. The pain began at the patient's home, prompting them to call for a 108 ambulance. Within ten minutes of receiving the call, the patient was shifted from their home to the ambulance by a bystander.

Patient Assessment:

Upon arrival, the EMT quickly assessed the patient's condition, including the intensity of pain, saturation, and blood pressure. They also prepared for potential complications to the mother after childbirth.

Pre-hospital management:

The patient was shifted into the ambulance, and vital signs were monitored. Within ten minutes of

transit, the patient's pain increased, and fluid leakage began, indicating imminent delivery. The EMT promptly instructed the Pilot to stop the vehicle and prepared the delivery kit. The delivery occurred at 11:10 am, after which the EMT attended to the newborn, clearing mucus and ensuring clear airways. Afterward, the patient was transferred to Alis Hospital for umbilical cord cutting, where 500ml NS IVF was administered. Upon stabilization, the patient was further transferred to MCH Trissur.

Patient condition at the time of handing over:

Following necessary interventions and continuous monitoring, the EMT observed slight improvement in the patient's condition. Vital signs, such as blood pressure and heart rate, were monitored, and the EMT ensured the

patient's secure transportation in the ambulance, providing appropriate care throughout the journey.

Reflection of the patient or patient relative:

The patient's family expressed gratitude for the EMT's prompt response and effective management, particularly in breathing and airway management. They appreciated the EMT's professionalism and swift actions during the emergency, which provided reassurance in a distressing situation. The family acknowledged the importance of the EMT's swift actions, which contributed to a positive outcome and alleviated concerns during the ambulance journey.



REFLECTION BY EMT : ANOOP GEORGE

Following the advice of ERCP, I successfully delivered the baby. I owe my competence to the training I received, for which I am grateful.

REFLECTION BY PILOT : PRASEETH

I prioritize safety while driving and ensure timely and secure transportation of patients, thereby performing effectively in my role.



CASE DETAILS

AMBULANCE LOCATION : VADAKKANCHERY CHC
 CASE ID : 4273
 DATE : 02- NOV-2023
 CALL TIME : 10.35 AM
 ERCP : DR. ALIS HOSPITAL
 RECEIVING HOSPITAL : Dr. ALIS HOSPITAL TRISSUR



A CASE OF FALL

NOVEMBER 2023

Details of the incident:

On November 15, 2023, our Emergency Response Centre received a call from a good Samaritan reporting an incident involving an unknown 45-year-old male who had skidded and fallen into a gorge approximately 100 feet high. Without delay, our Emergency Response Officer assigned the case to the Kallar Black Thunder location ambulance for assistance. The EMT and Pilot swiftly rescued the victim from the scene, utilizing additional resources as needed.

Patient Assessment:

Upon arrival at the scene, the EMT adhered to BSI precautions. During the initial assessment, it was observed that the victim was conscious and oriented. However,

the victim presented with a severe head injury, a left leg bone fracture, and multiple abrasions

Pre-hospital management:

The victim was immobilized and positioned in a supine position. A splint was applied to the fractured leg, and dressing was applied to the abrasion site. Oxygen administration was initiated at the scene. After stabilization, the victim was transferred into the ambulance. Inside the ambulance, vital parameters were assessed and recorded, and an IV cannula was securely inserted.

Patient condition at the time of handover:

The patient's condition improved significantly due to appropriate pre-

hospital management, with continuous reassessment conducted until the ambulance reached the hospital. The patient was safely admitted to the Government General Hospital in Mettupalayam for further management.

Reflection of the patient or patient relative:

The public played an active role in the rescue process, and they expressed appreciation for the timely services provided by the EMT and Pilot. The victim also expressed gratitude for having their life saved.



REFLECTION BY EMT : DHARSHINI

It was a critical case; the victim was in unstable condition. We immediately stabilized the victim and safely admitted to the hospital.

REFLECTION BY PILOT : MR. SURESH

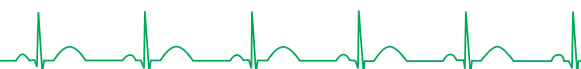
I supported to the EMT in providing the pre hospital care and I moved the ambulance quickly to the hospital to save the victim's life.



CASE DETAILS

AMBULANCE LOCATION : KALLAR BLACK THUNDER
 CASE ID : 3274864
 DATE : 15-11-2023
 CALL TIME : 09 :09 HRS
 ERCP : DR. SHIVANI
 RECEIVING HOSPITAL : GOVERNMENT GENERAL HOSPITAL, METTUPALAYAM .

PATIENT RECEIVING PRE-HOSPITAL CARE



Details of the incident:

On 11th November 2023, at 09:50 hrs, a tragic incident was reported at Kantathmakur village, Nadiikuda Mandal of Hanamkonda (Old Warangal District). Under the influence of alcohol, Mr. Bairone Veeramallaiah aged 70, due to family problems; went to commit suicide by stabbing his abdomen region using a sharp object. In this process, after seeing the blood and feeling the pain he started shouting. The family members, who were in another room came and after seeing him with bad bleeding injuries immediately called our 108 service to help and care for the victim.

Patient Assessment:

On reaching the scene, EMT Mr. V Sanjeeva performed a brief trauma assessment and found the victim Mr. Bairone Veeramallaiah was conscious

and had the penetrated impaled object (Knife) at the right lower quadrant abdomen region, involving the small arteries, leading to severe bleeding.

Pre-Hospital Management:

EMT Mr. V Sanjeeva with the help of Pilot Mr. Pamula Raju, applied the bulk sterile dressing pads and gauze for controlling the bleeding also immobilizing the penetrated Impaled object (Knife) and shifted him carefully into the ambulance by using the scoop stretcher, high flow oxygen was initiated. Baseline vitals were recorded; BP 110/70 mm of Hg, Pulse rate 92/min and Respiratory rate 26/min. ERCP Dr. Srikanth was contacted; on his advice, IV RL was initiated and Injections of Tramadol IM were given for pain relief.

Patient condition at the Time of

Hand over:

En route, the EMT Mr. V Sanjeeva did a reassessment of the condition of the victim Mr. Bairone Veeramallaiah and found to be stable. With proper Pre-hospital care and close monitoring, the victim was transported to The Mahatma Gandhi Memorial (MGM) Hospital of Warangal for further surgical care and management.

Reflection of the Patient or Patient relative:

Our Associates later learnt from the 48hrs follow-up and further recent enquiry, that the victim underwent surgery for removal of penetrated impaled object (Knife) and was in ICU for one week. Later he recovered in a special ward under the specialist's observation of the same Hospital. The hospital staff appreciated all the Pre-Hospital Care and humanitarian services of 108.



REFLECTION BY EMT : VAKKALA SANJEEVA

The Hospital duty doctors appreciated our good Pre-Hospital Care and our best timely efforts in saving the life of the victim. We feel very proud of our work and thankful to our EMRI GHS organization for giving us such a great opportunity in a life-saving mission.

REFLECTION BY PILOT : PAMULA RAJU

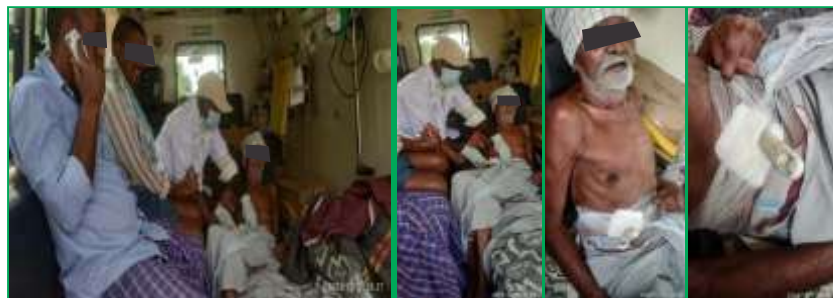In follow-up, we felt very happy and satisfied, when we saw the victim recovering at the special ward of MGM Waragnal and also we had a conversation with him. The victim and family members praised us a lot for saving his life, and appreciated our good services and sincere efforts.



CASE DETAILS

AMBULANCE LOCATION : PARKALA
 CASE ID : 202301136075832
 DATE : 11/11/2023
 CALL TIME : 09:50
 ERCP : DR. SRIKANTH
 RECEIVING HOSPITAL : MAHATMA GANDHI
 MEMORIAL (MGM)
 HOSPITAL, WARANGAL

PATIENT RECEIVING PRE-HOSPITAL CARE IN 108 AMBULANCE



Details of the incident:

An incident took place in Fatehpur District, resulting in an individual sustaining injuries. Initially, the victim was transferred to CHC Khaga. However, due to the critical nature of the case, the victim was subsequently referred to the District Hospital Fatehpur for further treatment and management.

Patient Assessment:

Upon arrival at the hospital, the patient was critically injured, with a head injury and in an unconscious condition. The EMT then received proper handover from the hospital staff and safely transferred the victim into the ambulance.

Pre-hospital management:

The EMT promptly initiated appropriate interventions by transferring the patient into the

ambulance. Vital signs were measured by the EMT, revealing the patient's baseline readings as follows: BP 110/72 mmHg, Pulse 72 beats per minute, respiratory rate 14 breaths per minute, and 96% SPO2. ERCP was immediately contacted, and under their medical direction, the EMT commenced IV fluid RL administration. With continuous monitoring of the patient and vitals recorded every 5 minutes, the patient was transported to the destination hospital, District Hospital Fatehpur.

Patient condition at the time of handing over:

Following the implementation of necessary interventions and continuous monitoring en route, the victim's condition improved upon arrival at the hospital. Anxiety levels were decreasing, and vital signs showed improvement upon reaching

the hospital.

Reflection of the patient or patient's relative:

The prompt response to an emergency is greatly appreciated, as the ambulance staff efficiently and effectively cared for the patient. Their quick actions in this case enabled us to save the patient's life. The ambulance staff received heartfelt appreciation from the patient's attendant for their commendable efforts.



REFLECTION BY EMT : MANOJ KUMAR

I reached to the scene, shifted patient into the ambulance, and took vitals, treated as per the ERCP advice then admitted to District Hospital Fatehpur.

REFLECTION BY PILOT : SHOBHIT


After case assignment I started ambulance immediately and reach scene and shifted patient to the hospital.



CASE DETAILS

PATIENT RECEIVING PRE-HOSPITAL CARE IN 108 AMBULANCE

AMBULANCE LOCATION : CHC KHAGA
CASE ID : 2023111095795
DATE : 04/11/2023
CALL TIME : 08:50 HRS
ERCP : Dr. HARISH
RECEIVING HOSPITAL : DISTRICT HOSPITAL FATEHPUR



DECEMBER - 2023

Details of the incident:

An incident took place in Farrukhabad District, involving a five-month-old baby experiencing breathing difficulties. Initially, the baby was transferred to RML Hospital Farrukhabad. However, due to the severity of the case, the baby was referred to Saifai Medical College in Etawah for advanced treatment and management.

Patient Assessment:

The EMT and Pilot arrived at the hospital to find a five-month-old baby experiencing severe respiratory distress.

Pre-hospital management:

The EMT promptly initiated appropriate interventions by transferring the patient into the ambulance. Vital signs were assessed by the EMT, revealing a baseline pulse

of 62 beats per minute, respiratory rate of 28 breaths per minute, and SpO2 level of 31%. Recognizing the critical nature of the condition, characterized by extremely low oxygen levels and a sinking pulse, the EMT swiftly administered high-flow oxygen to the patient. Despite this intervention, the SpO2 level did not significantly improve.

The EMT immediately contacted ERCP for medical direction. Following their guidance, the EMT initiated positive pressure ventilation through a Bag Valve Mask (BVM). With the assistance of the BVM device, the baby's condition gradually improved, and the SpO2 level increased to 92%.

Continuously monitoring the baby and assessing vitals every 5 minutes, the EMT ensured the maintenance of positive pressure ventilation through

the BVM device throughout the transport to the destination hospital, Saifai Medical College in Etawah.

Patient condition at the time of handing over:

Following the implementation of necessary interventions and continuous monitoring en route, the baby's condition showed improvement upon arrival at the hospital. Vital signs had improved by the time of arrival at the hospital.

Reflection of the patient or patient's relative:

Our baby was severely ill and struggling to breathe properly. The EMT's excellent work instilled hope in us during this challenging time.



REFLECTION BY EMT : KAMAL

It was challenging as well as satisfying experience for me to safely transport such a critical case to the Hospital. Refresher training and ERCP Support made me confident to deal with such a typical case.

REFLECTION BY PILOT : SHAILENDRA

Understanding the criticality of the patient, I drove ambulance safely fast and reached the hospital in time. It gives immense pleasure to help the sufferers.



CASE DETAILS

PATIENT RECEIVING PRE-HOSPITAL CARE IN 108 AMBULANCE

AMBULANCE LOCATION : RML HOSPITAL FARRUKHABAD
 CASE ID : 763853
 DATE : 31/12/2023
 CALL TIME : 12:01 HRS
 ERCP : DR. G. P. KUSHWAHA
 RECEIVING HOSPITAL : SAIFAI MEDICAL COLLEGE ETAWAH



A CASE OF RTA

DECEMBER 2023

Details of the incident:

On December 11, 2023, at 10:57, our emergency response center received a call from Colvale road, Thivim, reporting a road traffic accident. Mapusa ambulance was the nearest available unit. Upon gathering scene details, the EMT and Pilot quickly proceeded to the scene with the required equipment to administer necessary pre-hospital care. While en route, the EMT advised the caller to apply direct pressure to control any external bleeding and instructed them not to feed the patient orally. Ensuring scene safety and maintaining BSI precautions, our team promptly arrived at the scene.

Patient Assessment:

Upon initial assessment, it was determined that a 47-year-old male had been involved in an accident. The EMT swiftly conducted a rapid trauma

survey and identified an open right tibia fibula fracture, along with abrasions on the right knee and ear. Immediate wound care and splinting were administered to the patient, and external bleeding was promptly controlled. Meanwhile, the EMT consulted ERCP as the patient's condition was critical. ERCP guided the EMT, advising on wound care, external bleeding control, positioning for comfort, IV access, administration of IV fluid NS, and monitoring of vital signs.

Pre-hospital management:

Following ERCP's instructions, the injured area was dressed and splinted, and the patient was carefully transferred into the ambulance on a spine board. Without delay, the EMT recorded the patient's vitals, which were found to be within normal limits. Wound care was administered to the

patient, with all interventions performed by the EMT as advised by ERCP.

Patient condition at the time of handing over:

After implementing the necessary interventions and continuously monitoring the patient, the EMT noticed an improvement in the patient's condition. The EMT provided reassurance to the patient throughout the journey. Upon reaching the destination hospital, the patient was handed over to the casualty department of Asilo Hospital.

Reflection of the patient:

Saving someone's life is an incredibly gratifying experience. Being selected for the EM Care Award is truly a momentous occasion for me.



REFLECTION BY EMT : SAYLEE PARAB

It was a case of RTA, the victim was conscious but bleeding. Pre-hospital care Management was done. With the support of Pilot, we have shifted the patient.

REFLECTION BY PILOT : YOGESH TARI

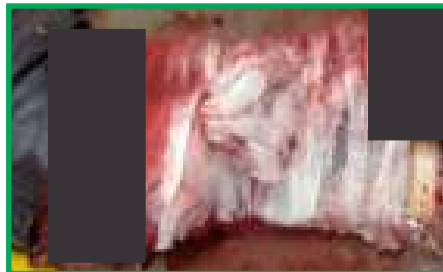
I am proud to say that I am a pilot of 108, in this noble profession I am privileged to do social service through this platform.



CASE DETAILS

PATIENT RECEIVING PRE-HOSPITAL CARE IN 108 AMBULANCE

AMBULANCE LOCATION : MAPUSA DISTRICT HOSPITAL NORTH
GOA
CASE ID : 20231200007096
DATE : 11/12/2023
CALL TIME : 10:57
ERCP : FAREEMA
RECEIVING HOSPITAL : ASILO HOSPITAL



Details of the incident:

On December 19, 2023, Payalben Parmar's baby was delivered around 12:30 hrs. Shortly after birth, the doctor observed that the baby was experiencing respiratory distress and had a low birth weight. Additionally, the baby had two episodes of convulsions. Recognizing the need for ventilatory support, the doctor at Civil Hospital, Nadiad promptly contacted 108 services at around 07:19.

Patient Assessment:

Upon arriving at the scene, the EMT observed that the baby was intubated, and the doctor has administering Bag Valve Mask Ventilations due to the baby's bradypnea and hypoxia.

Pre-hospital management:

The EMT promptly continued administering Bag Valve Mask (BVM) ventilation in the proper position and

transferred the patient into the ambulance with the assistance of the Pilot and relatives. During a subsequent reassessment, the EMT observed that the baby's pulse had decreased to 54 beats per minute. Without delay, the EMT initiated Cardio Pulmonary Resuscitation (CPR) using BVM and oxygen. Upon the return of spontaneous circulation, the EMT contacted ERCP Dr. Roopchand Ramani multiple times for online medical direction. Following Dr. Ramani's advice, the EMT administered Inj. Atropine in the proper dilution and continued BVM ventilation. Vital signs were assessed, with the following readings: Respiration Rate 36 breaths per minute, Pulse Rate 147 beats per minute, SpO2 98%, and RBS 110 mg/dl.

Patient condition at the time of handing over:

Following the implementation of all necessary interventions and continuous monitoring, the patient was transported to the 1200-bed Civil Hospital Asarwa, Ahmedabad, covering a distance of approximately 60 km. Upon handover, the patient was stable, and there was a remarkable improvement in his vital signs.

Reflection of the patient or patient's relative:

The relatives expressed heartfelt appreciation for the efforts made by both the EMT and the pilot.



REFLECTION BY EMT : RUTWIK PATEL

I am filled with joy and gratitude as our case has been chosen as a savior for the first time. I relied on the knowledge and skills acquired during my training to handle this case effectively. I extend my sincere thanks to 108 EMRI GHS for granting me the opportunity to serve in such a meaningful capacity. Additionally, I am grateful to my Pilot for their invaluable assistance in this life-saving mission. Our teamwork undoubtedly played a crucial role in managing this critical patient amidst such a challenging situation.

REFLECTION BY PILOT : SUNIL PARMAR

I am deeply proud and overwhelmed to be chosen as a Savior for this month. My gratitude extends to everyone who deemed me worthy of participating in this life-saving mission. This award serves as a powerful encouragement, driving me to work with even greater enthusiasm and confidence. I consider myself fortunate to be part of the EMRI GHS Organization.



CASE DETAILS

BABY RECEIVING PRE-HOSPITAL CARE IN 108 AMBULANCE

AMBULANCE LOCATION : UTTARSANDA
CASE ID : 20230120212788
DATE : 19/12/2023
CALL TIME : 13:15 HRS
ERCP : DR. ROOPACHAND RAMANI
RECEIVING HOSPITAL : 1200 BED CIVIL HOSPITAL, ASARWA, AHMEDABAD



A CASE OF RTA

DECEMBER 2023

Details of the incident:

On December 15, 2023, a call was received from bystanders who witnessed a 47-year-old male involved in a two-wheeler accident near the main market road of Dharwad city. They activated 108 services and requested medical assistance for the severely injured individual. The case was assigned to the Annigiri PHC location ambulance, staffed with EMT-Manjunath and Pilot-Raju.

Patient Assessment:

Upon arrival at the scene, the EMT discovered that the victim had sustained a head injury, a right knee injury, and irregular lacerations with severe bleeding. Despite the injuries, the patient remained conscious and alert. Using the spinal motion restriction device (SMRD), the victim was carefully transferred into the ambulance. Bleeding was assessed and controlled using direct pressure techniques. Baseline vital signs were recorded, revealing a pulse of 104 bpm, blood pressure of 130/60 mmHg,

respiratory rate of 22 breaths per minute, and SpO2 of 94%.

Pre-hospital management:

The EMT assessed the patient's vitals, which were recorded as follows: Blood pressure: 130/60 mmHg, Pulse rate: 104 beats per minute, Respirations: 22 breaths per minute, and SpO2: 94%. ERCP Dr. Priyanka was contacted, and the EMT followed her instructions for pre-hospital care. Pre-hospital Management included: Oxygen administration at 6 liters per minute, Intravenous fluid (IVF) RL at a rate of 20 drops per minute, wound care, Bleeding control, Injection of PCT 1000mg intramuscularly, Splinting and bandaging of injuries

Patient condition at the time of handing over:

Following the implementation of necessary interventions and continuous monitoring, the EMT observed an improvement in the victim's condition. The patient appeared comfortable, and

bleeding was controlled effectively. Vital signs, including blood pressure and heart rate, stabilized within normal ranges. The EMT ensured the patient was securely placed on the stretcher, ready for a smooth handover to hospital staff upon arrival. Subsequently, the patient was transferred to KIMS Medical College Hospital. Doctors commended the EMT and Pilot for their exemplary efforts in saving the patient's life.

Reflection of the patient or patient relative:

The patient and their family members expressed heartfelt gratitude for the EMT's prompt response and effective management of the victim. They appreciated the EMT's professionalism, calm demeanor, and the reassurance provided during such a distressing situation. The patient and their family members recognized the significance of the EMT's swift actions during the ambulance journey, which played a crucial role in saving the life of a young victim.



REFLECTION BY EMT : MANJUNATH

It was a case of RTA & the victim was conscious but bleeding. Pre hospital care Management was done. My Pilot Raju supported during the emergency. It was a great help in shifting the patient.

REFLECTION BY PILOT : MR. RAJU

I am happy to save the precious life & proud to be in EMRI Green Health Services of Karnataka.



CASE DETAILS

PATIENT RECEIVING CARE IN 108 AMBULANCE

AMBULANCE LOCATION : ANNIGIRI PHC,
DHARWAD DIST
CASE ID : 12229
DATE : 15-12-2023
CALL TIME : 21:42PM
ERCP : DR. PRIYANKA
RECEIVING HOSPITAL : KIMS MEDICAL
COLLEGE HOSPITAL.



DECEMBER 2023

A CASE OF CHEST PAIN

Details of the incident:

On December 6, 2023, a relative of the patient contacted our Emergency Response Centre, informing us that his 47-year-old brother was experiencing severe chest pain. Without delay, our Emergency Response Officer assigned the case to the Nambiyur PHC location ambulance for immediate assistance.

Patient Assessment:

Upon arrival at the scene, the EMT adhered to BSI precautions. During the initial assessment, the patient was conscious and oriented. He exhibited symptoms of severe chest pain, which radiated to the left side of the shoulder region. Additionally, he was experiencing excessive sweating and complaining of breathing difficulty.

Pre-hospital management:

Our EMT provided reassurance to

the patient and ensured they were in a comfortable position. High-flow oxygen was administered at the scene to aid in stabilization. Once the patient was stabilized, they were carefully transferred into the ambulance. Inside the ambulance, vital parameters were checked and recorded, and an IV line was secured. Advice was sought from ERCP, and in accordance with their guidance, the patient was given Tab. Aspirin 150 mg orally.

Patient condition at the time of handover:

The patient's condition was continuously monitored, and with appropriate pre-hospital management, the pain gradually reduced. Reassurance was provided to the patient throughout the journey to the hospital. Consciousness level and vital parameters were regularly

assessed to identify any potential complications. Upon arrival at the Government General Hospital in Gobichettipalayam, the patient was safely admitted for further management.

Reflection of the patient or patient relative :

The patient conveyed his appreciation to the EMT and Pilot for delivering proper prehospital care and offering psychological support, which helped alleviate fear and ensured he felt safe and comfortable



REFLECTION BY EMT : MR. GOWRINATH

It was a great satisfaction to me and Pilot to provide the good pre hospital care to the patient.

REFLECTION BY PILOT : MR. DHAYANITHI

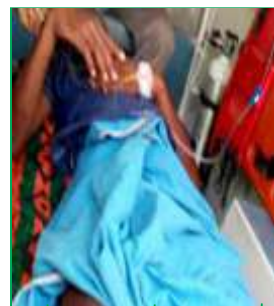I felt happy for saved the patient life during his critical condition.



CASE DETAILS

PATIENT RECEIVING CARE IN 108 AMBULANCE

AMBULANCE LOCATION : NAMBIYUR PHC
CASE ID : 3508931
DATE : 06-12-2023
CALL TIME : 02 :38 Hrs
ERCP : DR. MEERA
RECEIVING HOSPITAL : GOVERNMENT GENERAL HOSPITAL,
GOBICHETTIPALAYAM



A CASE OF RTA

DECEMBER 2023

Details of the incident:

On December 2nd, 2023, at 11:40, a tragic road traffic accident involving a lorry overturning was reported in Dharmapuri Mandal Headquarters of Jagitial (formerly Karimnagar District). Mr. Shaik Razak was driving the lorry, transporting loaded Rice Paddy bags from Jagitial to the Dharmapuri warehouse. While negotiating a turn on the main road at Akkasaipalle Ghat downhill, the lorry experienced brake failure, resulting in loss of control and overturning. Mr. Razak sustained serious injuries in the incident. Bystanders witnessing the accident promptly alerted the 108 emergency services and informed the Police.

Patient Assessment:

Upon arrival at the scene, EMT Mr. Anil Kumar conducted a rapid scene size-up and assessed the victim, Mr. Shaik Razak, aged 55. Despite being

conscious, Mr. Razak had a deep laceration on his right-hand humerus and crush injury on his left leg below the knee joint, both of which were bleeding profusely. Additionally, he had multiple abrasions across his body.

Pre-Hospital Care and Management:

EMT Mr. Anil Kumar, assisted by Pilot Mr. MD Qhaum Ali, promptly took measures to control bleeding from the crush and laceration injuries by applying pressure bandages. They also immobilized Mr. Razak's neck with a C-Collar and transferred him to the ambulance using a scoop stretcher. High-flow oxygen was initiated, and baseline vital signs were recorded: BP 130/70 mm Hg, Pulse rate 94/min, and Respiratory rate 23/min. ERCP Dr. Durga Prasad was consulted, and as per his guidance, IV RL was initiated in the left arm, and Injections Rantac and Tramadol IM were administered for pain relief.

Patient Condition at Handover:

During transportation, EMT Mr. Anil Kumar reassessed Mr. Razak's condition and found him to be stable. Accompanied by Police personnel, Mr. Razak was safely transferred to The District Hospital Jagitial (formerly Karimnagar District) for further surgical intervention and management.

Patient or Patient Relative Reflection:

Subsequent follow-up and recent inquiries revealed that Mr. Razak underwent surgery to amputate his left leg up to the knee joint due to the severity of the crush injury. Under the care of orthopedic specialists and two weeks of specialized treatment, Mr. Razak made a full recovery and returned home to recuperate.



REFLECTION BY EMT : POTHU ANIL KUMAR

The victim was so scared about the injuries after the lorry overturned. We reassured him and provided timely Pre-Hospital Care by following proper protocols. We feel very proud for saving his life.

REFLECTION BY PILOT : MA QHAUM ALI

We kept all the good efforts and followed all the protocols in shifting the victim. It was a great satisfaction to help the victim in such a critical condition. We feel happy while all Police officials, bystanders and receiving hospital staff appreciate our good efforts.



CASE DETAILS

1. PAPER CLIPPING 2. VICTIM INJURY & PRE-HOSPITAL CARE PHOTOGRAPHS

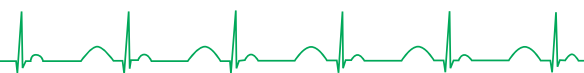AMBULANCE LOCATION : CHC DHARMAPURI
 CASE ID : 20230036010859
 DATE : 02/12/2023
 CALL TIME : 11:40
 ERCP : DR. DURGA PRASAD
 RECEIVING HOSPITAL : DISTRICT HOSPITAL JAGITIAL



Hon'ble Chief Minister of Uttar Pradesh Shri. Yogi Adityanath Launched 674 New 102 Ambulances on 5th December 2023



EMRI GHS was Honoured with Asian Covid Warrior Award under Institutional Category 6th Asian EMS Conference at Tokyo, Japan on 30th November 2023,



Hon'ble Chief Minister of Gujarat Shri. Bhupendrabhai Patel Launched 25 New Mobile Veterinary Units on 10th November 2023



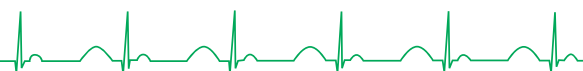
Hon'ble Chief Minister of Gujarat Shri. Bhupendrabhai Patel Launched 47 New 181 Abhayam vans on 4th November 2023



Hon'ble Chief Minister of Karnataka Shri. Siddaramaiah launched 262 New 108 Ambulances on 30th November 2023



EMRI GHS UP Team Felicitated the Best Performers from both 108 and 102 Ambulance Services on 4th November 2023



Hon'ble Chief Minister of Rajasthan Shri. Ashok Gehlot Launched 100 New 112 Police Mobile Units on 5th October 2023



Hon'ble Chief Minister of Rajasthan Shri. Ashok Gehlot Launched 100 New 108 Ambulances on 5th October 2023





EMRI GREEN HEALTH SERVICES

Devar Yamzal, Medchal Road, Secunderabad - 500 078 Telangana, India.

Tel : + 91 40 2346 2600, 2346 2602 - Fax 2346 2178

www.emri.in