

EM CARE

Towards saving lives and bringing hope

CALL 108
EMERGENCY
• MEDICAL • POLICE • FIRE

Spreading... **SMILE**

Partnering States and Union Territories



Towards Saving Lives and Bringing Hope...

Launched on 15th August 2005 in Hyderabad and expanded to 2 Countries
In India 16 States and 1 Union Territory.



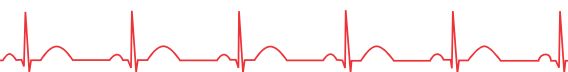78,339 CALLS ANSWERED EVERY DAY



27,212 EMERGENCIES RESPONDED PER DAY FLEET OF 14,212 AMBULANCES BY TRAVELLING DISTANCE OF 10,74,281 KM PER DAY 9,28,97,558 EMERGENCIES RESPONDED



47,01,616 LIVES SAVED SINCE INCEPTION. 6,00,313 DELIVERIES ASSISTED BY EMTs.



New year- New Hope

GVK EMRI-Rajasthan has added 55 new Basic Life Support (BLS) ambulances to its existing operations which were inaugurated by government officials of Rajasthan on 10th January'2022. These additional ambulances will strengthen access to more number of emergency victims. On 12th January'2022, Honourable Union Health Minister, Shri Mansukh Laxmanbhai Mandaviya visited Tamil Nadu GVK EMRI office and carried out an inspection of 108, 104 control rooms along with COVID helpline. Union Health Minister appreciated the great work done by GVK EMRI emergency services towards defeating COVID 19. On 26th January ,73rd Republic Day was celebrated in all operating states with zeal and enthusiasm by remembering India's occurrence as an independent republic.



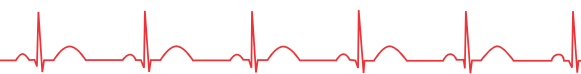
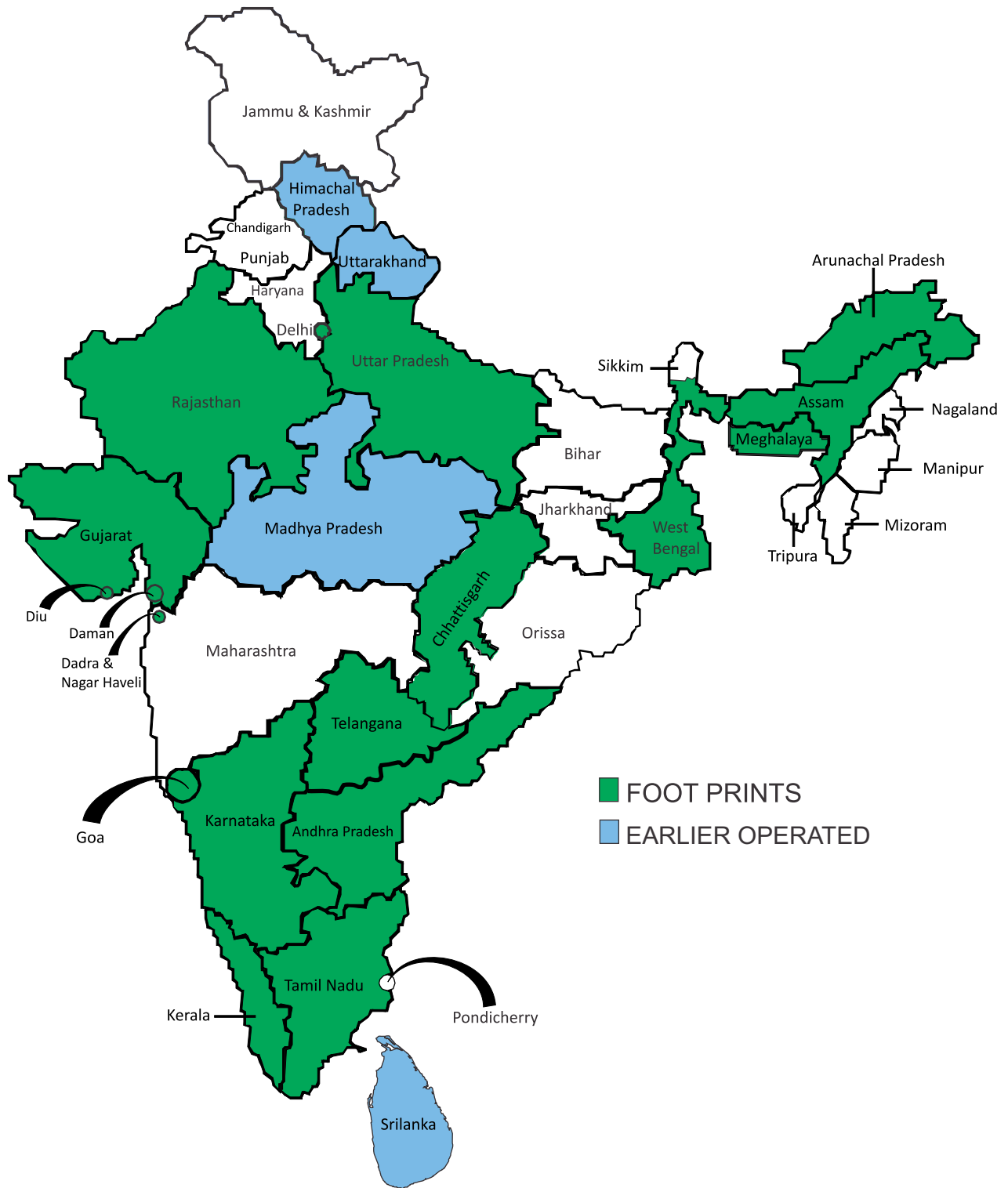
On 23rd February'2022, Honourable Chief Minister of Tamil Nadu Shri M.K. Stalin launched 188 new 108 ambulances to boost the existing ambulances to ensure access to healthcare. The total number of ambulances under 108/ 102 projects in TN is now close to 1500. In the state of Telangana, GVK EMRI has extended his medical services by deploying 15 BLS ambulances and 5 Bike ambulances to the biennial tribal fair - Sammakka and Sarakka Jathara at Medaram from 15th February to 20th February'2022 and attended total 1387 cases.

In the month of March'2022, GVK EMRI has commenced its 1st Air Ambulance services in Gujarat. It was inaugurated by Union Minister of Civil aviation Shri. Purnesh Modi and state minister of civil aviation Shri. Arvind Bhai Raiyani on 21st March. The air ambulance service will be jointly operated by the state health department and GVK-EMRI. Patients will be transferred from state to state for further Medical services. On 30th March'2022, Honourable Health Minister of Telangana Shri Harish Rao has inaugurated new 108 ambulances for better reaching the people of Telangana. On 20th March'2022, honourable Chief Minister of Assam Dr Himanta Biswa Sarma, held brief review on GVK EMRI services wherein he appreciated the services and expressed useful ideas to strengthen further.

By the of March 2022, GVK EMRI has provided over 25.2 lac COVID 19 linked transfers. Average transfers per day since the beginning of pandemic was observed to be nearly 3300. Precaution dosage or booster dose against COVID 19 was also observed to be significantly picking up amongst ambulance staff being recognized under the frontline workers' category. Dr Vinod Paul, Member NITI Aayog communicated a note appreciating the ambulances services of GVK EMRI during the peak of COVID 19 pandemic and use of herbal drugs for ambulance staff to boost the immunity of staff. New Year 2022 is for sure is creating a new hope for restoration of normalcy in all walks of life after almost two years of global struggle against the COVID 19 pandemic.

My sincere appreciations to Telangana, Tamil Nadu & Gujarat teams who were selected as 108 saviours for the months of January, February and March'2022.

With best wishes
K. Krishnam Raju
DIRECTOR - GVK EMRI





108 attends over 2,50,000 calls per day and 97% calls gets picked-up before 2 rings.

Aiming to reduce the neonatal mortality rate, GVK EMRI has launched Neonatal Ambulance equipped with all the facilities to shift newborns to emergency care.



Neonatal Ambulance



Drop-back Ambulance

To reduce infant & maternal mortality rate, "Drop-back Ambulances" are being inducted into service to shift newly born babies to their home in a sterile condition.

Specifically targeted to reach the people of rural areas, "Mobile Medical Units" meets the healthcare needs of individuals who may not have transportation or access to hospitals, clinics or medical offices.



Mobile Medical Unit (MMU)



Boat Ambulance

For quick response to medical emergencies in riverine areas and during floods, GVK EMRI has introduced "Boat Ambulances".

Dedicated for providing Inter Facility Transfer (IFT), these ambulances shift patients from one Hospital to another in case of emergencies.



Inter Facility Transfer (IFT)



Doli-palki

To access hilly terrains where there is minimal or no road connectivity, "Doli-palki" is a novel thought conceived and implemented by GVK EMRI.

In case of any health emergency, "Call 104" is the service which provides information and advice pertaining to primary action need to be taken.



To hinder crime rate and ensure peace in the society, GVK EMRI's "Dial 100" has deployed high-end technology for analyzing calls, better information gathering, prompt response, follow up and faster information sharing across various levels.

To help women in distress and block increasing crime rate against women, "Call 181" is a new service dedicated to women needing help through counselling and reaching out.



Aiming to save animal lives and strengthen livelihoods of poor farmers in the country, GVK EMRI introduced "Animal Ambulances/Mobile Veterinary Clinics". They provide doorstep emergency veterinary care for livestock and stray animals and can shift the animal to a specialist facility if required for better care.

Physical Progress

S. No	Name of the State Government	No of Ambulance	Emergencies Since Inception	Emergencies Attended in March 2022	Deliveries Assisted by EMT since Inception	Deliveries Assisted by EMT in March 2022	Lives saved since Inception	Lives saved in February 2022
1	Telangana	423	74,78,539	44,460	66,174	511	3,82,530	3,489
2	Gujarat	800	1,32,62,758	1,01,778	1,17,507	734	12,24,285	9,517
3	Goa	52	6,41,009	4,403	1,050	5	44,709	310
4	Tamil Nadu	1,353	1,28,08,072	1,24,801	50,697	587	9,17,457	349
5	Karnataka	746	96,84,533	51,727	56,351	85	5,95,058	1,003
6	Assam	793	57,62,552	30,846	48,653	149	1,83,757	866
7	Meghalaya	50	2,29,764	981	2,512	12	27,102	81
8	Diu Daman & Dadra Nagar Haveli	22	3,36,881	3,253	1,260	10	15,975	118
9	Uttar Pradesh	2,200	2,10,10,614	4,00,625	94,470	65	7,08,917	0
10	Rajasthan	815	41,66,217	32,751	20,755	41	0	0
11	Kerala	330	4,92,647	12,141	53	4	0	0
12	Delhi	237	8,36,819	35,467	0	0	0	0
13	Arunachal Pradesh	84	3,537	350	12	4	0	0
National		7,905	7,67,13,942	8,43,583	4,59,494	2,207	41,36,143	15,733

108 State wise completed projects:

State	Project Tenure	Emergencies Handled	Assisted Deliveries	Lives saved
Himachal Pradesh	Dec'2010 - Jan'2022	15,03,762	12,978	1,39,042
Madhya Pradesh	July'2009 - Sep'2016	37,82,608	27,505	98,251
Kerala	Apr'2014 - Nov'2015	73,143	34	-
Andhra Pradesh	Aug'2015-Dec'2017	72,66,356	70,531	2,72,891
Uttarakhand	May'2008-Apr'2019	13,87,711	15,075	33,458
Chhattisgarh	Jan'2011-Nov'2019	20,55,075	14,669	58,184
Total		1,60,68,655	1,40,792	6,01,826

Janani Shishu Suraksha Karyakram (Mother & Child)

S. No	Name of the State Government	No of Janani Ambulance as on March 2022	Janani Beneficiaries Since Inception	Janani Beneficiaries March 2022
1	Assam	235	22,92,113	25,041
2	Gujarat	467	69,47,910	1,99,868
3	Andhra Pradesh	175	14,97,740	14,999
4	Telangana	300	41,55,126	1,13,625
5	Chhattisgarh	324	60,20,921	54,891
6	Uttar Pradesh	2415	5,00,76,131	10,74,695
7	Goa	1	8,002	14
8	West Bengal	981	25,05,858	74,487
9	Tamilnadu	99	12,45,600	17,259
Total		4,852	7,47,49,401	15,74,879
Per Day Calculation		50,803	Dispatches/ Day	

Note: Rajasthan Janani Express (JSSK) Project (2016-2021) completed by Feb'2021 and total beneficiaries **41,64,718** since



108 Saviour of GVK EMRI - INDIA

JANUARY	:	TELANGANA TEAM	-	A CASE OF ELECTROCUTION	08
FEBRUARY	:	TAMIL NADU TEAM	-	A CASE OF FALL	18
MARCH	:	GUJARAT TEAM	-	A CASE OF BURNS	28

STATE WISE CASE OF THE MONTH

JANUARY	:	ASSAM TEAM	-	A CASE OF UNCONSCIOUS	09
JANUARY	:	GUJARAT TEAM	-	A CASE OF CRITICAL DELIVERY FOLLOWED BY NNR	10
JANUARY	:	GOA TEAM	-	A CASE OF UNCONSCIOUS	11
JANUARY	:	KARNATAKA TEAM	-	A CASE OF RTA	12
JANUARY	:	KERALA TEAM	-	A CASE OF DELIVERY	13
JANUARY	:	MEGHALAYA TEAM	-	A CASE OF RTA	14
JANUARY	:	TAMIL NADU TEAM	-	A CASE OF DELIVERY	15
JANUARY	:	UTTAR PRADESH TEAM	-	A CASE OF RTA	16
FEBRUARY	:	ASSAM TEAM	-	A CASE OF RTA	19
FEBRUARY	:	GUJARAT TEAM	-	A CASE OF POISONING	20
FEBRUARY	:	GOA TEAM	-	A CASE OF HYPOGLYCEMIA	21
FEBRUARY	:	KARNATAKA TEAM	-	A CASE OF RTA	22
FEBRUARY	:	KERALA TEAM	-	A CASE OF DELIVERY	23
FEBRUARY	:	MEGHALAYA TEAM	-	A CASE OF RTA	24
FEBRUARY	:	TELANGANA TEAM	-	A CASE OF RTA	25
FEBRUARY	:	UTTAR PRADESH TEAM	-	A CASE OF RTA	26
MARCH	:	ASSAM TEAM	-	A CASE OF RTA	29
MARCH	:	GOA TEAM	-	A CASE OF NEONATAL RESUSCITATION	30
MARCH	:	KARNATAKA TEAM	-	A CASE OF RTA	31
MARCH	:	KERALA TEAM	-	A CASE OF DELIVERY	32
MARCH	:	MEGHALAYA TEAM	-	A CASE OF ASSAULT	33
MARCH	:	TAMIL NADU TEAM	-	A CASE OF HANGING	34
MARCH	:	TELANGANA TEAM	-	A CASE OF RTA	35
MARCH	:	UTTAR PRADESH TEAM	-	A CASE OF RTA	36

NOT FOR PROFIT ORGANISATION OPERATING IN PUBLIC PRIVATE PARTNERSHIP MODEL

A CASE OF ELECTROCUTION

JANUARY 2022

On 03rd January 2022, at 14:45 hrs, a major electrocution accident took place at Pachunoor village, Manakondru Mandal of Karimnagar district. Master Aravind is flying a kite in front of his house. Near his house, there is a power supply electrical transformer fixed on a Pedestal (at a height of 3 feet) without any fencing, while in the process of flying his kite, got stuck on to the electric lines of Transformer. Master Aravind went near the transformer to get his kite back, unknowingly, he started to climb the pedestal of the transformer and he got electrocuted. This incident was due to electric shock, he was thrown off onto the road, due to the shock, started shouting and crying. The family members after listening to his crying sound ran towards him and saw the electrical burn injuries, immediately they called our 108 services to help and caring for him.

On reaching the scene, the EMT Mr. Chiranjeevi gathered the information about the incident and came to know that victim Master Aravind aged 12, conscious, electrocuted by high voltage (30 KVA) line. Due to the electrocution, he had severe electrical burns, and the entry points of the current on the left arm, exit points were seen on the both the lower limbs of the foot regions. EMT with the help of Pilot Mr. Ravi provided the wound care by using the sterile pads soaked in normal saline solution and gauze bandage dressings, applied C-Collar. The victim was carefully shifted into the ambulance by using the scoop stretcher with all precautions and high flow oxygen was initiated.

Baseline vitals were recorded, ERCP Dr. Eshwar was contacted for guidance, on his advice, IV NS was connected to the right arm; Injection Rantac and Injection

Tramadol IM were given. The victim was then shifted to The District General Hospital of Karimnagar District for further her surgical care and management. The family members of the victim later had decided to shift the him by private ambulance to the Life Line Hospital of Karimnagar for higher care and surgery for advanced burns.

Our Associates later learned from the followup and further recent inquiry, came to know that at Life Line Hospital, the victim's left arm was amputated up to the elbow joint region, the right arm and lower limbs were carefully managed, he was in the special ward under the specialist's observations of the hospital for one month recovered completely, went back home and taking rest.



REFLECTION BY EMT : CHIRANJEEVI CHEERA

"In my 09 years of experience, I have handled so many electrocution cases, but it was a major case of Electrocutation with high voltage of 30 KVA, with severe electrical burns, leading to amputation and other injuries. At the incident site, we have taken all the scene safety measures. It is our great experience to save the victim by providing timely pre-hospital care by following our protocols and ERCP advice. We feel very proud to save such major accident victims because of our training and association with the GVK EMRI organization. The Hospital personnel and victim's family members had highly appreciated our timely Pre-Hospital care."

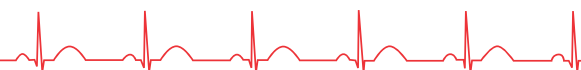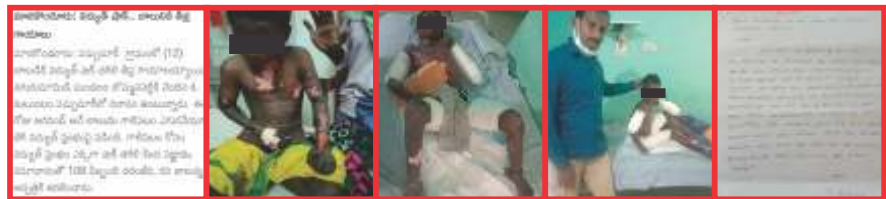REFLECTION BY PILOT : RACHARLA RAVI

"It was a great satisfaction to help the child in such a critical condition and we shifted him to the nearest hospital by giving proper timely pre-hospital care. We feel happy for being a Pilot in these life-saving missions of GVK EMRI. Villagers, family members, and hospital personnel appreciated our good services and sincere efforts."



CASE DETAILS **MEDIA COVERAGE, VICTIM INJURY, RECOVERY AND APPRECIATION LETTER:**

AMBULANCE LOCATION : GP OFFICE MAIN ROAD,
MANAKONDUR
CASE ID : 2022000048812
DATE : 03/01/2022
CALL TIME : 14:45 HRS
ERCP : DR. EASWAR
RECEIVING HOSPITAL : DISTRICT GENERAL
HOSPITAL, KARIMNAGAR



JANUARY 2022 A CASE OF UNCONSCIOUS

A 52 year old Udai Baishya was suffering from Hypertension for last few years with having a history of stroke. On 18 Jan 2022, he started feeling numbness on the left side of the body and started vomiting. Looking at his condition his family member dialed 108 seeking medical help.

The case was assigned to Veterinary Hospital Mukalmua Location of Nalbari District. Within a short time the team of 108 ambulance comprising of EMT Azadur Rahman and Pilot

Akkas Ali reached the scene. EMT found the patient was unconscious, lying in bed and in critical condition. So, without any delay, EMT quickly get him into the ambulance and checked his Vitals. The base vital signs were recorded as BP-110/70 mm of Hg, pulse -96 bpm, RR-14 bpm, SPO2-95%. Frothing was coming from the mouth and facial droop were seen. Based on the signs, EMT suspected it is a case of stroke.

Taking advice from ERCP Dr Anupam Borgohain,

suctioning was done, and oxygen was administered by the EMT. Providing pre-hospital care and with constant monitoring the vital parameters continued during the transport and patient was handed over safely to GMCH.



REFLECTION BY EMT : AZADUR RAHMAN

Stroke cases need correct diagnosis as the sign and symptoms are very confusing and I was able to do it right due to the high quality of training imparted to us by our organization. I am grateful to GVK EMRI for that.

REFLECTION BY PILOT : AKKAS ALI

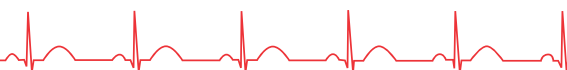
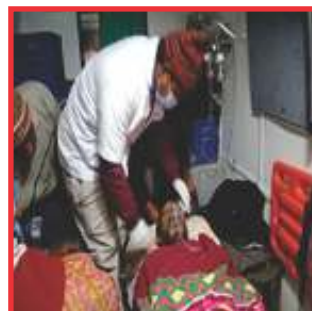Stroke is a life-threatening emergency and so such patients need urgent treatment at a higher center, so my job became very important as I am responsible for the save and prompt transport of the patient.



CASE DETAILS

PATIENT RECEIVING PRE-HOSPITAL CARE IN 108 AMBULANCE

AMBULANCE LOCATION : VETERINARY HOSPITAL MUKALMUA
 CASE ID : 20220100136892
 DATE : 18/1/2022
 CALL TIME : 07:18 HRS
 ERCP : DR. ANUPAM BORGOHAIN
 RECEIVING HOSPITAL : GMCH



A CASE OF CRITICAL DELIVERY FOLLOWED BY NNR

JANUARY 2022

35 years old Ms. Lila Parmar, who resides in Moti Boru village, Taluka Dholka, District Ahmedabad, started complaining of intense labor pain on 10th Jan 2022 at around 10:00 PM and went to Mirani Hospital, where she was registered for delivery. Due to unavailability of medical staff, they refused to take her in and around 11:00 PM, she delivered the baby outside of Mirani Hospital. One of the bystander immediately dialed '108' and requested for an ambulance. This case was assigned to the ambulance located at Tarapur manned by EMT Dhaval Patel and Pilot Mahesh Valand & the ambulance was dispatched immediately. While on their way, EMT requested the caller to cover the baby and avoid attempts to pull out the Placenta.

On arrival at the scene, EMT found that the mother was in altered mental status with retained placenta and the newborn was completely cyanosed and umbilical cord was around the neck. EMT Dhaval immediately cut the umbilical cord and started Cardio Pulmonary Resuscitation with Bag Valve Mask Ventilation. Pilot Mahesh Valand transferred the mother in the ambulance with the help of relatives. In the ambulance,

mother's vitals were assessed which were as follows: SpO2 was 86%, RR was 36 breaths/min, PR was 138 beats/min and Blood Pressure was 40/30 mm of Hg. Newborn's vitals were as follows: Pulse 30 beats/min, RR 04 breaths/min and Temperature 86.6 degrees Fahrenheit.

En route to the hospital, Firstly, EMT warmed the baby by turning on the Halogen lamp and continued CPR and BVM with Oxygen administration with the help of relatives as the baby was in cardiac arrest. Secondly, EMT also gave shock position and tried to remove placenta but could not remove it. EMT guided relative for uterine massage and accessed IV line in both hands. Lastly, after a complete assessment of the vital health parameters, EMT contacted Emergency Response Centre Physician Dr. Ashish twice, for online medical direction and as per his advice; EMT continued CPR and ventilations and gave Inj. Atropine and Inj. Adrenaline IM. Dr. Ashish also gave instructions to start IV fluids RL and NS with Inj. Oxytocin in the infusion for the mother. On reassessment, the Mother's vital signs had improved and it were as follows: SpO2 was 88%, RR was 34 breaths/min, PR was 130 beats/min and Blood Pressure was

50/40 mm of Hg. EMT had continuously monitored the vitals and both the patients were rapidly shifted to Civil Tarapur, Anand.

At CHC Tarapur, Medical Officer tried to remove the placenta, but he failed to do it and the newborn's condition was also worsening, so he requested EMT to shift both the patients in Shree Krishna Medical Hospital, Anand.

During hospital handover, Mother's SpO2 was 94%, RR was 30 breaths/min, PR was 124 beats/min and Blood Pressure was 66/58 mm of Hg. Newborn's vitals were as follows: RR was 10 breaths/min, PR was 38 beats/min and the Temperature was 94.8 degree F.

On 48 hour follow-up, it was reported that the mother and newborn were recovering without any complications. Thanks to the dedicated and coordinated efforts of the '108' team that saved precious lives.



REFLECTION BY EMT : DHAVAL PATEL

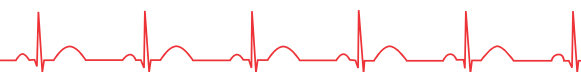I am extremely happy to have been selected as the Savior. I handled this case with the knowledge and skills gained during my training. Receiving savior award has given me happiness and inspiration to keep working hard in emergency field. I really thank our organization for giving me an opportunity to serve. I also thank my Pilot Mahesh Valand for helping me in this life saving mission.

REFLECTION BY PILOT : MAHESH VALAND

I am grateful, as our case has been selected as the savior of the month. In this case, I helped EMT Dhaval in providing Newborn and Mother Care. I thank all who have given me this opportunity for saving lives and serving people. This really gives me lots of satisfaction.

CASE DETAILS PATIENT RECEIVING PRE-HOSPITAL CARE IN 108 AMBULANCE

AMBULANCE LOCATION : TARAPUR
 CASE ID : 20220100116858
 DATE : 10/01/2022
 CALL TIME : 01:26 HRS
 ERCP : DR. ASHISH
 RECEIVING HOSPITAL : SHREE KRISHNA MEDICAL HOSPITAL, KARAMSAD



JANUARY 2022 A CASE OF UNCONSCIOUS

On 1st Jan 2022 at 05:00, Dhargalim ambulance got a call from ERC saying there was a 75 years old female patient Mrs. Jijabai Rane with complaints of fainting and loss of consciousness at Ibrampur North - Goa.

The case was assigned to EMT Mrs. Dipa and Pilot Mr. Sanjeev. After which they rushed immediately on the scene. After reaching on the scene and ensuring the scene was safe, EMT then did the initial assessment in which she found

that the patient was covid positive, unconscious and with shortness of breath. Immediately EMT checked her vitals which is as follows:

The Vitals of the patient were as follow : LOC Unconscious, Pulse 68beats/min, Blood pressure 130/70 mm Hg, Respirations 10 breaths/min, SPO2: 84% GRBS: 20 mg/dl, TEMP: A febrile.

Patient was shifted in the ambulance with the help of Pilot. ERCP conference was taken and Dr. Aaron advised to administer

6 L /mi n O x y g e n , IV access, Dextrose 25% stat, monitor vitals and shift. EMT followed the advice. Patient was then shifted to PHC Sanguem. After 48 hrs of follow up patient was found alive and in good medical condition.



REFLECTION BY EMT : DIPA WARANG

It was a great moment for me, where in I get a chance to make use of my skills. I would like to thank my organization for having faith in me that I can do better in this career of medical field.

REFLECTION BY PILOT : SANJEEV K. PARAB

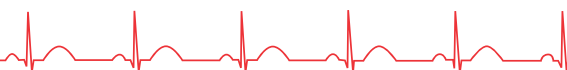
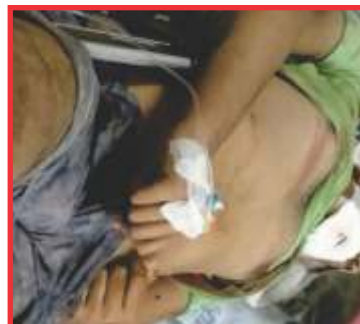I am grateful to my organization for recognizing my efforts in this event of saving lives. I shall keep doing the good work and further help save many more lives.



CASE DETAILS

AMBULANCE LOCATION : DHARGALIM RTO CP
 CASE ID : 20220100005755
 DATE : 06/01/2022
 CALL TIME : 05:00 HRS
 ERCP : DR. ARON
 RECEIVING HOSPITAL : ASILO HOSPITAL, MAPUSA

PATIENT RECEIVING PRE-HOSPITAL CARE IN 108 AMBULANCE



A CASE OF RTA**JANUARY 2022**

On 6th January 2022 at around 03 : 31 pm , 108 - Emergency Response Center (ERC) received a call from a Good Samaritan from Chithradurga District, who was very frightened by the sudden event and requested for an ambulance urgently. On enquiring about the case details by our Emergency Response Officer (ERO) a 45 years old male had multiple severe injuries on his body. Luckily the nearest available ambulance was Aimangala location ambulance manned with EMT Arunkumar and Pilot Sudhakara on duty. The crew reached the incident location which was 10km away within 8 minutes. On reaching the location and enquiring about the history of the incident, it was understood that the victim was in a car driving towards

the bypass. During this processes an oncoming truck from the opposite direction hit the car.

EMT Arun realized the emergency condition and asked the bystanders to clear the scene & Pilot to shift the victim into ambulance to prevent further infectious complications during the rescue operation. Victim was shifted into ambulance with scoop stretcher. During the assessment the victim was found unconscious state associated with a wide irregular laceration with bleeding on the right side of the head & an open left clavicle fracture masked with multiple abrasions. A laceration was on left arm, splinting was applied with all precautionary measures. An IV line was accessed and started IVF-RL fast flow.

Baseline vitals were recorded, BP-100/60 mm of Hg, Pulse-136bpm,RR-16 breaths/min, SPO2-98%, the victim was diaphoretic & unconscious. On consultation with ERCP Dr. Aniketh Oxygen was started at 12 lts/min. Victim was shifted to Chithradurga DH Hospital. Doctors appreciated EMT & Pilot for their presence of mind and the accurate pre-hospital management which was given to the victim at the scene & in the ambulance enroute before reaching the hospital.

Patient relatives showered blessing and their gratitude towards our ambulance team.

**REFLECTION BY EMT : ARUN KUMAR**


The case was a very critical RTA case & one of my first experiences to deal victims with such severe injuries and I was very nervous and thought it would be difficult to handle here as the crowd was huge & forcing us to shift the victim and move the ambulance. I felt very satisfied for saving the life of a victim who suffered severe bleeding injuries. I got good support from Pilot Sudhakar and I am proud to be associated with GVK EMRI.

REFLECTION BY PILOT : SUDHAKARA

I am immensely proud to have saved a life & it was the most memorable case I have ever come across. This was my first encounter in my service to deal with such an incident. I am proud to be associated with GVK EMRI.

**CASE DETAILS**

AMBULANCE LOCATION : AIMANGALA
CASE ID : 2857005
DATE : 06-01-2022
CALL TIME : 15:31 HRS
ERCP : DR. ANIKETH
RECEIVING HOSPITAL : DH CHITRADURGA

PATIENT RECEIVING PRE-HOSPITAL CARE IN 108 AMBULANCE

JANUARY 2022

A CASE OF DELIVERY

Varsha Mohan, 30, a resident of Trivandrum District Vithura Njaraneeli Shaneesa Bhavan, gave birth to a baby boy inside KANIV 108 ambulance on Monday. The incident took place around 1 am. Due to labor pains, Varsha was rushed to Vithara Taluk Hospital by her relatives. She was immediately referred to SAT hospital for specialist treatment. Doctor sought the services of KANIV 108 ambulance. Following the information from the control room, Kaniv 108 Ambulance Pilot Ananthan SA and EMT Shiji

Jose rushed to the hospital and transferred Varsha to the ambulance. While reaching a place called Chennanpara, Varsha's health had deteriorated and in the examination of EMT Shiji Jose, it is noted that Varsha was in the primary stage of Delivery. EMT made necessary arrangements to attend the delivery inside the ambulance and at 1.19 am, Varsha gave birth to a baby boy under Shiji's care. Immediately after giving first aid, Pilot Anandan rushed the mother and baby to Vithara Taluk Hospital and later was

shifted to SAT hospital.



REFLECTION BY EMT : SHIJI JOSE

I was confident that I can handle the situation and make sure that the mother and newborn are safe

REFLECTION BY PILOT : ANANTHAN SA

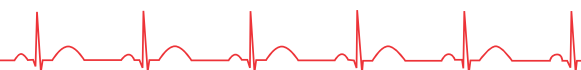I am glad that the lives of both mother and child are saved by us.



CASE DETAILS

AMBULANCE LOCATION : VITHURA TALUK HOSPITAL
 CASE ID : 20220100029572
 DATE : 10/01/2022
 CALL TIME : 01:11 HRS
 RECEIVING HOSPITAL : SAT HOSPITAL, TRIVANDRUM

MEDIA COVERAGE



A CASE OF RTA

JANUARY 2022

On the 1 January 2022, two individuals were traveling in a truck which is also loaded with logs and planks. They were on their way to the state capital, Shillong, from West Khasi Hills District. Transporting goods from one district to another is their livelihood. The driver was experienced and have a good knowledge of the roads of the State, evenjungle roads . This knowledge has helped him to avoid troubles in his journeys. But bad luck can also happen to the best of men. That day was not just another day for them. On reaching the Sohiong bypass, their truck over turned completely. It happened so suddenly that both of them had no time to come out. While the driver, received only minor injuries, the handyman could not come out of the truck by himself anymore. Though it happened just 2

hours after midnight, still the villagers living in the vicinity of the accident site, rushed to the scene and helped the victims. On seeing the condition of the handyman, they dialed the number 108.

After receiving the information from the patient party, the ERO immediately at 02:13 AM assigned the case to the 108- ambulance based at Mairang CHC. EMT Shane Khongriat, EMT on duty and Pilot John Section Nongsiej, Pilot on duty quickly rushed to the scene for attending to the case. On reaching the scene, the EMT saw that the patient was conscious but lying motionless on the roadside. The victim was Romsoh Kurbah, a 23 years old male. After positioning and stabilizing the patient they hurriedly shifted the patient inside the ambulance. In the

ambulance, a thorough assessment was done. The patient was having a huge laceration on the right temporal region which is bleeding continuously. Bruise in both the eyebrows. Could not move his lower limbs with the complaint of pelvic pain. The patient was immobilized from head to toe. Wound care was done and a pelvic binder was applied. The EMT, after assessment of the patient called for Online Medical Direction and received instruction from Dr J Nongtdu. Oxygen was given at 6 liters per minute. The patient was transported initially to Mairang Civil Hospital but due to the criticality of the case, the patient was shifted to Shillong Civil Hospital.

On 48 hour follow up, the patient is still in hospital but greatly improved in condition.




REFLECTION BY EMT : SHANE KHONGRIAT

It is always difficult to manage critical trauma victims in ambulances. Thanks to the trainings I received and the care protocols which help me to handle this case with confidence.

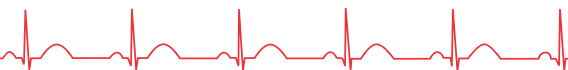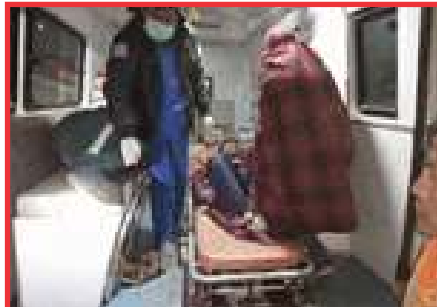REFLECTION BY PILOT : JOHN SECTION NONGSIEJ

I am happy that as always, we were the first to be remembered by people in distress. The relatives of the victim were living far away from the scene. Calling 108 was the first thing they did when they knew of the incident.



CASE DETAILS **PATIENT RECEIVING PRE-HOSPITAL CARE IN 108 AMBULANCE**

AMBULANCE LOCATION : MAIRANG BASE
CASE ID : 2022000004618
DATE : 01/01/2022
CALL TIME : 02:13 HRS
ERCP : DR. J NONGTDU
RECEIVING HOSPITAL : SHILLONG CIVIL HOSPITAL



JANUARY 2022

A CASE OF DELIVERY

On 28 January 2022, our Emergency Response Centre received a call from Thuvananthapuram GH requesting ambulance for an IFT to Government General Hospital, and Trichy. A 20 year old 2 gravid An anemic mother who had a severe abdominal pain. The mother had a history of G2P1LOA0D1 and the expected date of delivery is on 26/02/2022. Our Emergency Response Officer assigned the case to nearest location ambulance for the pre-hospital care.

On arrival at the hospital, BSI precautions were followed by the EMT. On assessment, the mother was conscious and oriented. EMT assessed the mother's vital signs which were stable. Then the mother

immediately shifted into the ambulance. The left lateral position was maintained and the IV line was secured.

En route to the hospital, the intensity and frequency of labor pain increased and crowning was present. As advised by ERCP, immediately the ambulance was parked in a safer location. Our EMT encouraged the mother to push the baby. As soon as the mother delivered the baby's head. EMT assessed and found that the cord wrapped around the neck of the baby. Immediately our EMT gently removed the cord from the neck by using the cord removal technique and delivered the baby. It was a male baby. EMT sanctioned the

baby's airway, and dried and wrapped the baby using a blanket. The baby was kept under the warmer. The baby's weight is around 3kgs.

Placenta delivered and assessed. The bleeding was within normal limits. The third stage of labor was actively managed with medications and IV fluids. The mother and the baby were continuously monitored till the ambulance reaches the hospital. The mother and the baby were safely shifted to Government General Hospital, Trichy for further management.



REFLECTION BY EMT :MANIMEKALA

I felt very happy for conducting the delivery. The mother and her family thanked 108 services for the timely support.

REFLECTION BY PILOT : RENGASAMY

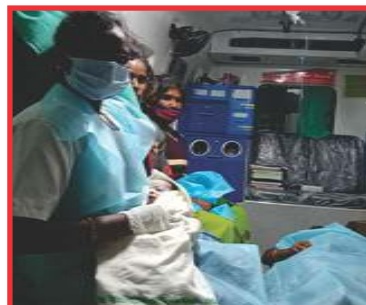I understood the mother's situation and parked the ambulance in a safer location. I am glad being a part of saving lives.



CASE DETAILS

MOTHER & BABY RECEIVING PRE-HOSPITAL CARE IN 108 AMBULANCE

AMBULANCE LOCATION : VALANADU PHC
 CASE ID : 298182
 DATE : 28/01/2022
 CALL TIME : 23:15 HRS
 ERCP : DR. KALYAN
 RECEIVING HOSPITAL : GOVERNMENT GENERAL HOSPITAL, TRICHY.



A CASE OF RTA

JANUARY 2022

ERC received a call at 17.34 PM for 2 wheeler road traffic accident where a single victim was injured.

With the information given by caller, EMT Mr. Santosh Kumar Bhartiya and Pilot Mr. Indrajit Yadav rushed to the scene with consideration of requirements at scene and having contact with caller frequently to assist the patient.

Considering safety at the scene EMT found the victim was lying supine on the roadside with multiple injuries having minor

bleeding, With bleeding controls EMT assessed the victim was unconscious with a patent airway and adequate breathing and having deep laceration on the head, multiple injuries in the upper and lower extremities e.g. lacerations and abrasions.

With proper immobilization of the victim's body victim was shifted to the ambulance with oxygen inhalation. Vital signs were obtained by EMT and recorded as BP- 76/46 mmHg Pulse Rate-42 beats /min RR-13/min and SPO2-78%. EMT took expert advice from

Dr. H.P. Khare and as per the advice, IV fluid RL, Inj. Dexamethason, inj. Deriphylline and oxygen were given to the patient with a dressing of the wounds over the body surface area.

During transportation, continuously monitoring of the victim was done by the EMT and safely admitted to the SRN Hospital Prayagraj.

Victim found alive and improved on 48 HRS follow-up.



REFLECTION BY EMT : SANTOSH KUMAR BHARTIYA

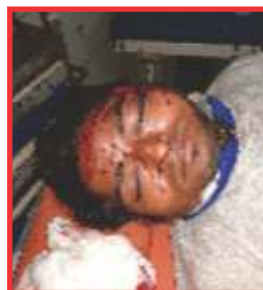The condition of victim was very serious. Under the guidance of ERCP and help of bystanders, we were successful in saving patients life.

REFLECTION BY PILOT : INDRAJEET YADAV

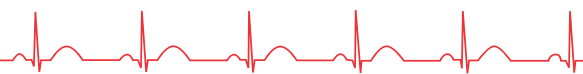After getting case ID we moved quickly, and reached at scene and saved time to increase survival rate of victim, I am feeling grateful.

CASE DETAILS PATIENT RECEIVING PRE-HOSPITAL CARE IN 108 AMBULANCE AND MEDIA COVERAGE

AMBULANCE LOCATION : P.S.JHUSI, PRAYAGRAJ
 CASE ID : 198020
 DATE : 10/01/2022
 CALL TIME : 17.34 AM
 ERCP : DR. H.P. KHARE
 RECEIVING HOSPITAL : S.R.N.H,PRAYAGRAJ



सड़क हादसे में युवक घायल, एसआरएन में भर्ती
 झुंसी। धन शेष के कटका गांव के पास सोमवार को अज्ञात वाहन की चपेट में आने से वाइक सवार युवक गंभीर हो गया। हादसे की सूचना मिलने पर 108 एम्बुलेंस कर्मचारियों ने युवक को एसआरएन अस्पताल में भर्ती कराया। गैरपुरी के मंगला कुआं श्रमा भागाव निवासी वॉरेंट 30) पुत्र शुभु दयाल कपड़े की मिर्री लगाता है। वह साधियों के साथ कोहरा में किराये के मकान में रहता है। सोमवार को वॉरेंट कपड़े बेचने के लिए झुंसी आया था। कटका गांव के पास अज्ञात वाहन ने वाइक में टक्कर मार दी। संवाद



FEBRUARY 2022

A CASE OF FALL

FEBRUARY 2022

On 7 February 2022, our Emergency Response Center received a call for a 2 years old boy child who accidentally fell into an empty well from the height. The incident occurred during the construction work. The metal rod impaled the the victim's mouth and exited to his upper back. The child had severe pain and bleeding. Immediately our Emergency Response Officer assigned the case to Chengal pattu local town location ambulance for the immediate support.

The child was rescued from an empty well by the construction workers before the ambulance

reaches the scene. On reaching the scene, BSI precautions were followed by the EMT. On assessment, the EMT found that the child was drowsy. The child was frightened and seemed to be restless. The child had a penetrating injury, where the metal rod has been impaled in the child's mouth and exited to his posterior thoracic region. The child had severe pain and bleeding. Immediately our EMT controlled the bleeding and applied the bulky dressing to immobilize the impaled object. Airway was cleared by suctioning. After stabilization, the child was loaded into the ambulance. Vital parameters

were checked and observed as tachycardia, hypotension, and hypoxia. Oxygen was administered and an IV line was secured.

En route to the hospital, our EMT obtained the ERCP advice. As per the advice of an ERCP, fluids were administered and cleared the airway, frequent suctioning was done. The child was safely shifted to the Government Medical College and Hospital, Chengalpattu for the further management.

On 48 hour follow up, the child was stable and on continuous monitoring.



REFLECTION BY EMT : JENISHA

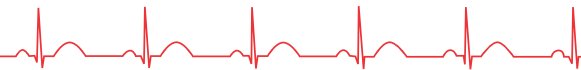
EMT Reflection: I am working with 108 GVK EMRI since few months, in training we learnt so many important things like that have made me confident to tackle any kind of emergency.

REFLECTION BY PILOT : BHARATH KUMAR

Pilot Reflection: I assisted the EMT to save a child's life. and I moved the ambulance swiftly and safely to the hospital.

CASE DETAILS PATIENT RECEIVING PRE-HOSPITAL CARE IN 108 AMBULANCE

AMBULANCE LOCATION : CHENGALPATTU LOCAL TOWN
 CASE ID : 390629
 DATE : 07/02/2022
 CALL TIME : 17:01 HRS
 ERCP : DR. SHIVANI
 RECEIVING HOSPITAL : GOVERNMENT MEDICAL COLLEGE AND HOSPITAL, CHENGALPATTU.



FEBRUARY 2022

A CASE OF RTA

Road traffic accidents are major cause of mortality in our country. Such as a major case of RTA occurred in Dibrugarh District on 18th Feb 2022 at around 3 PM. 45 Years old Mr. Probin Baruah was severely injured, facing a Road Traffic Accident while he was on the way to his home riding the Motorcycle.

The bystanders call the 108. The ERO assign the case to Chabua Location of Dibrugarh District. EMT Mr. Nibaran Gogoi and Pilot Mr. Suleman Ali immediately rushed to the scene and found

that Mr. Baruah was unconscious & severely injured in right hand, leg and arm. Right-hand fracture with penetrate, open wound and heavy bleeding. The vitals recorded are as follows: BP / 140/90 mmHg, Pulse / 90/min, RR / 16/min, SPO2 / 97%.

After taking ERCP advice from Dr. Anupam Borgohain, EMT stopped the bleeding by using gauze pads followed by wound care and splinting was done to the fractured hand. Pain management was done and administered IV fluid NS during


transportation as per the advise. Patient was closely monitored during transportation and handed over to Assam Medical College and Hospital.



REFLECTION BY EMT : NIBARAN GOGOI

RTA cases are always critical as they involve head injury and fracture and we take extra care in handling such cases.

REFLECTION BY PILOT : SULEMAN ALI
 Quick and safe transport of RTA cases are very vital for survival of such patient. My responsibility increases manifold in this regard, I always try to do my best in such cases.



CASE DETAILS **PATIENT RECEIVING PRE-HOSPITAL CARE IN 108 AMBULANCE**

AMBULANCE LOCATION : CHABUA
 CASE ID : 20220200137243
 DATE : 18/02/2022
 CALL TIME : 03.10 HRS
 ERCP : DR. ANUPAM BORGHAIN
 RECEIVING HOSPITAL : ASSAM MEDICAL COLLEGE & HOSPITAL



A CASE OF POISONING**FEBRUARY 2022**

On 6 February 2022, 30 years old Ms. Saroj, who is a resident of Junagadh district was working on a farm when she attempted suicide by drinking pesticide poison. As soon as the people working with her came to know about this, one of them, Mr. Prakash, immediately called 108 and request for an ambulance. The ambulance located at Bheshan was dispatched for the case. EMT Divya Gosai and Pilot Rahul Pipaliya were on duty. After collecting all essential case details, they rushed to the incident location. While on the way, EMT instructed the caller to provide left lateral position, to not to give her anything by mouth and to move the poison away from the patient. After the preparation of necessary equipment, adequate BSI precautions were taken.

On arrival at the scene, Ms. Saroj was found to be responding only to pain and was frothing from the mouth. EMT Divya immediately started airway management with suction, insertion of a nasopharyngeal airway and promptly loaded her into the ambulance with the help of the pilot and relatives.

En route to the hospital, comfortable the position was given, IV access was done and oxygen was administered. In the ambulance, vitals were assessed which were as follows: Pulse rate 44 beats/min, Blood pressure 98/60 mm Hg, SpO2 65%, RR 08 breath/Min and RBS 90mg/dl. As Ms. Saroj had bradycardia, hypotension & hypoxia, EMT immediately started BVM with oxygen and contacted ERCP Dr. Jitendra two times and Dr. Zil three times over the

phone for online medical direction. As per their advice, EMT administered inj. Atropine, inj. Adrenaline, I.V Fluids and other EM Drugs.

First, the patient was taken to the nearest hospital CHC Bheshan, but the patient was very critical, so Medical Officer referred this patient to a higher facility hospital. With diligent observation and continuous monitoring, Ms. Saroj was finally shifted to Vadaliya hospital, Junagadh. At the time of handing over, the vital parameters had remarkably improved.

On a 48 hr follow-up call, it was reported that Ms. Saroj was at that time out of danger and was regaining her health. Thanks to the dedicated and coordinated efforts of the '108' team that saved her precious life.

**REFLECTION BY EMT : DIVYA GOSAI**

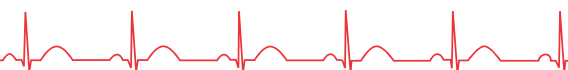
I am extremely happy to be selected as a Savior once again. Rewards are always delightful but saving a patient's life and bringing a smile to the faces of the patient's relatives gives me greater happiness. I would like to thank God and GVK EMRI for giving me this opportunity to save lives.

REFLECTION BY PILOT: RAHUL PIPALIYA

I am extremely happy for being selected as a Savior once again. Contributing to a lifesaving mission is always amazing for me and I feel very happy and blessed. Good teamwork makes miracles!

**CASE DETAILS****PATIENT RECEIVING PRE-HOSPITAL CARE IN 108 AMBULANCE**

AMBULANCE LOCATION : BHESAN
CASE ID : 20220200074057
DATE : 06/02/2022
CALL TIME : 13:16 HRS
ERCP : DR. JITENDRA & DR. ZIL
RECEIVING HOSPITAL : VADALIYA HOSPITAL, JUNAGADH



FEBRUARY 2022 A CASE OF HYPOGLYCEMIA

On 8th Feb 2022 at 18:04, Verna ambulance received a call from ERC stated that there was a case of an unconscious patient. On duty EMT and Pilot rushed to the scene and found that the patient named Nisha Pesnet 20 years old female lying on the bed.

Immediately EMT took control of the scene and requested everyone to vacate the room so that he can assess the patient and provide necessary intervention. EMT recorded baseline vital signs and found that the patient was unconscious

along with hypotension and hypoglycemia. The vital signs are as follows : L.O.C Unconscious, Pulse 68 beats /min, Blood pressure 80/60 mm Hg , Respirations 12 breaths/min, Spo2% 97% GRBS: 29 mg/dl, TEMP: A febrile.

Without any further delay EMT called ERCP, Dr. Navjyot, and on his suggestion EMT established IV line and started dextrose 25% and 1-pint normal saline stat and kept monitoring vitals after every 5 minutes. Fortunately the patient became conscious en

route and her vitals were stable. EMT then handed over the patient to new Hospicio. After 48 hours of follow up the patient were fully recovered.



REFLECTION BY EMT : VINOD BADASKAR

As a health care provider I feel proud that every day I am able to save lives of people who are in need.

REFLECTION BY PILOT : KALPESH L. PATIL

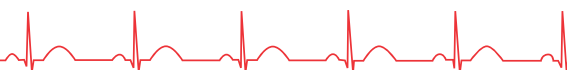
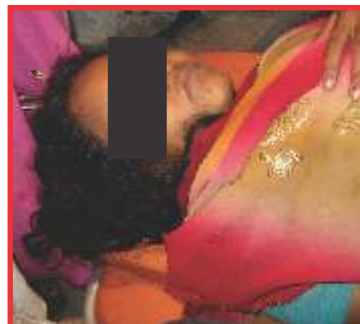This is my first EM care award, feeling happy! It was a great experience to handle such critical case.



CASE DETAILS

AMBULANCE LOCATION : VERNA PS
 CASE ID : 20220200005735
 DATE : 08/02/2022
 CALL TIME : 18:04 HRS
 ERCP : DR. NAVJYOT
 RECEIVING HOSPITAL : GMC BAMBOLIM

PATIENT RECEIVING PRE-HOSPITAL CARE IN 108 AMBULANCE



A CASE OF RTA**FEBRUARY 2022**

On 18 February 2022. 108-Emergency Response Center (ERC) received a call from a Good Samaritan of Chitradurga District, who was very frightened and requested for an ambulance urgently. On enquiring about case details, our Emergency Response Officer (ERO) got information of a 55 old victim encountered an accident. ERO immediately assigned the nearest available ambulance murugarajendramata location. EMT Harish and Pilot Manjunath rushed to the scene which was 10 km away. On reaching the location a tragic RTA was witnessed in which a heavy lorry had collided with a bike. EMT Harish realized the emergency condition and activated police line for help till the arrival of the police

team, EMT & Pilot commenced the processes to prevent further injury by shortened sharp rods with an angle grinder. With the help of police, victim was shifted in to the Ambulance for further management.

The wounds caused due to multiple penetrations & crushed mass were treated, fractures were stabilized by splinting after bleeding control. pelvic binder was applied with all precautionary measures, IV lines was accessed and started fluids RL with 60 drops/minute.

Baseline vitals were recorded via multi monitor which were, BP-100/80 mm of Hg, Pulse-140bpm, RR-16 breaths/min,

SPO2-95%, the victim was diaphoretic. On consultation with ERCP Dr. Sayed. Oxygen was started at 12 lts/min. Patient was shifted to the nearest hospital as his condition demanded higher emergency medical interventions. Receiving hospital doctors appreciated EMT & Pilot for their presence of mind and the accurate pre hospital management which was given to the victim at the scene & in the ambulance en route before reaching the hospital.

Patient relatives showered blessings and their gratitude towards our ambulance team. The condition of the victim was stable after 48 hours follow up.

**REFLECTION BY EMT : HARISH B**


The case was a critical one and my first experience dealing with a victim who had a pelvic injury. I was nervous and thought it would be difficult to handle here as the crowd was huge & forcing us to shift the victim and move the ambulance on speed. I felt very satisfied for saving the life of a victim who suffered severe bleeding injuries. I got good support from Pilot Manjunath and I am proud to be associated with GVK EMRI.

REFLECTION BY PILOT : MANJUNATH S

I am immensely proud for saving a life & it was my most memorable case I have ever come across. This was my first encounter in my service to deal with such incidence. I am proud to be associated with GVK EMRI.

**CASE DETAILS****PATIENT RECEIVING PRE-HOSPITAL CARE IN 108 AMBULANCE**

AMBULANCE LOCATION : MURAGARAJENDRAMATA
CASE ID : 380050
DATE : 18/02/2022
CALL TIME : 15:21 HRS
ERCP : DR. SAYED
RECEIVING HOSPITAL : CHITRADURGA DH



FEBRUARY 2022 A CASE OF DELIVERY

Timely response of Kaniv 108 Ambulance staff gave new life to a guest worker and her home born newborn baby. Saritha Devi, 30, wife of Kali Ram, a native of Hazaribagh, Jharkhand and currently residing in Adoor, has given birth to a baby boy at home. The incident took place around 7 am. On 14 February 2022, but due to her health condition they failed to shift her into a vehicle. They then contacted the local Asha worker. Meanwhile, Saritha gave birth to the baby at home. Asha worker who came to know

about the incident sought the services of Kaniv 108 Ambulance. The emergency message from the control room was immediately conveyed to Kaniv 108 Ambulance at Chengannur District Hospital. Ambulance Pilot KV Sunilkumar and EMT Siju Thomas Nainan reached the spot. Immediately, EMT Siju severed and tied the umbilical cord and transferred the mother and baby into the ambulance after giving post delivery care. Ambulance Pilot Sunil Kumar then shifted the two to Adoor General Hospital.

On 48 hours follow up, both mother and baby was found alive and discharged from the hospital.



REFLECTION BY EMT : SIJU THOMAS NAINAN

I am glad that the lives of mother and baby were safe.

REFLECTION BY PILOT : SUNIL KUMAR KV
I am glad that the lives of both mother and child were saved by us.



CASE DETAILS

AMBULANCE LOCATION : CHENGANOOR DH
 CASE ID : 20220200042303
 DATE : 14/02/2022
 CALL TIME : 07:13 HRS
 RECEIVING HOSPITAL : ADOOR GH

MEDIA COVERAGE



A CASE OF RTA

FEBRUARY 2022

On the 17 February, 2022, two individuals were traveling in a motorcycle in the outskirts of the town of Mairang. They are the employees of a bank. As they are being posted in the rural part of the State, their job is also to meet the clients in the villages. On reaching Mawshut village, they stopped their scooty in the roadside and one of them got down to buy something from a shop. His colleague was waiting for him in his scooty. Suddenly, a high speeding truck just appeared on the scene. It hit the scooty throwing the sole occupant into the air, who fell in the field many feet away. It ran over the other person outside the shop and crushed him beyond identification. Fortunately, the shopkeeper and the other villagers were not within the way of the truck. On seeing

the condition of the two bank employees, the villagers dialed the number 108.

After receiving the information from the patient party, the ERO immediately at 16:12 assigned the case to the 108-ambulance based at Mairang CHC. EMT Shane Khongriat, EMT on duty and Pilot John Section Nongsiej, Pilot on duty quickly rushed to the scene for attending to the case. On reaching the scene, the ambulance team went to check the more critical patient. As he was still beneath the wheels of the truck, crushed and no vitals were present, they now focused on the other patient. His name is Dibaye Jyoti, is a 28 years old male. He was conscious and complained of pains all over the body. No external injuries but could

not move his lower limbs with complaints of pelvic pain. The patient was immobilized from head to toe. A pelvic binder was applied. PMS was normal. The EMT, after assessment of the patient, called for Online Medical Direction and received instruction from Dr J Nongtdu. Oxygen was given at 6 liters per minute. The patient was transported to Mairang Civil Hospital. Later on, the patient was transported to GNRC hospital in Guwahati.

On 48 hour follow up, the patient is still in hospital but greatly improved in condition.



REFLECTION BY EMT : SHANE KHONGRIAT

In managing the road traffic accidents victims need a systematic approach that requires both life-saving care and avoiding further injuries to patients. Thanks to the training and protocols, which helped us to manage this case with confidence.

REFLECTION BY PILOT : JOHN SECTION NONGSIEJ

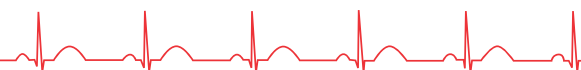
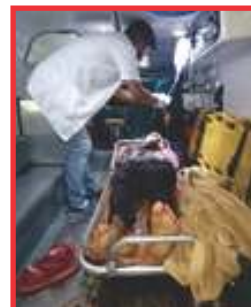Calling 108 is important. In many cases it is the only way to save the patients life.



CASE DETAILS

AMBULANCE LOCATION : MAIRANG BASE
 CASE ID : 20220000015505
 DATE : 14/02/2022
 CALL TIME : 16:12 HRS
 ERCP : DR. J NONGTDU
 RECEIVING HOSPITAL : MAIRANG CIVIL HOSPITAL

PATIENT RECEIVING PRE-HOSPITAL CARE IN 108 AMBULANCE



FEBRUARY 2022 A CASE OF RTA

On 15 February 2022, at 15:40 hrs, a road traffic accident was reported on Rajiv Rahadari Highway, near Mandapalli Village outskirts of Siddipet (Old Medak District). Mr. Ch Bhaskar along with his family members Mrs. Rajamma (Mother), Mrs. Tirumala (Wife), Mrs. Mounika (Daughter) and Mr. Amaresh (Son-In-Law) were traveling by his car from Karimnagar to Malkajgiri of Hyderabad, after attending a function at Karimnagar. Enroute near the village Mandapalli, while taking a deep curve, their car collided with the culvert, all of them sustained serious injuries. The bystanders called 108 services for helping, caring the victims and also informed the Police officials.

On reaching the scene, EMT Mr. Mahender performed rapid scene size up, taking the help of police to control the crowd and traffic establishing scene safety. He assessed the victim Mr. Ch Bhaskar aged 38, who drove the car, semiconscious had a head injury with deep laceration on the forehead, the site of the injury was bleeding severely and his left leg was completely stuck beneath

the dashboard. At steering point. He requested the Police personnel for bringing in a welder for extrication of the victim. EMT with help of Pilot Mr. P Ramesh taken immediate steps of controlling the bleedings of laceration wound by applying sterile pads and pressure bandages, under aseptic conditions, applied C-Collar and then contacted ERCP Dr. Lavanya explained the situation of the victim in the cabin, she advised IV fluids initiated and maintained the vitals carefully, the total extrication process took more than two hours at the scene, after which the victim was carefully lifted and shifted into the ambulance by using of scoop stretcher, provided wounds care, done splinting to fractured left limb for immobilization and high flow oxygen was initiated. The baseline vitals were recorded; BP 100/70 mm of Hg, Pulse rate 96/min and Respiration rate 26/min. EMT informed about the baseline vitals and as per the advice ERCP, Injection Rantac and Injection Tramadol IM was given for pain relief. With constant monitoring, the victim was shifted to the District Hospital of Siddipet (Old Medak District) for

further surgical care and management. While our ambulance staff were attending on the main victim, Mr. Gangula Kamalakara (Hon' ble Minister of Telangana State), who was passing on the same highway, stopped his convoy, taken information about the accident and instructed his convoy officials to shift the remaining victims (four), who had minor injuries, after providing the wound care by our ambulance staff in their convoy vehicles to District Hospital Siddipet. The family members of the victim later had decided to shift the victim by a private ambulance to the private Hospital of Secunderabad for better care and advance surgery.

Our Associates later learned from the follow-up and further recent inquiry victim Mr. Ch Bhaskar had undergone surgery of his left leg due to fracture and he was in the observation of orthopedic specialists, after special care for one week recovered completely, went home and took rest.



REFLECTION BY EMT : MAHENDER BAINDLA

"It was a tragic incident to see the victims in that situation, on seeing the damage of the car on the scene, it's fortunate that with careful planning of the extrication, we could save the victim after that so much time and provide the timely good pre-hospital care, with help of Pilot Mr. P Ramesh and other bystanders, shifted him very carefully into the ambulance and reached the nearest hospital within a short period. We feel very proud and more confident that we did all the best possible care, because of the training in saving such lives. Thanks to the GVK EMRI Organization for giving us this opportunity to help out the needy people in EMS."

REFLECTION BY PILOT: RAMESH PANJALA

"We reached the victim very shortly and shifted the victim in to the ambulance and transported safely to the nearest hospital. In follow up, we had conversation with victim family members, we felt very happy and satisfied, when we heard about victim recovered completely and taking rest at his home. Victim family members praised a lot for saving his life appreciated our good services and sincere efforts."



CASE DETAILS

AMBULANCE LOCATION : SUB CENTRE DUDDEDA
 CASE ID : 20220000816857
 DATE : 15/02/2022
 CALL TIME : 15:40 HRS
 ERCP : DR. LAVANYA
 RECEIVING HOSPITAL : DISTRICT HOSPITAL SIDDIPET.

MEDIA COVERAGE, VICTIM INJURY, RECOVERY AND APPRECIATION LETTER



A CASE OF RTA

FEBRUARY 2022

This was a road traffic accident where a car dashed the bike and a 65-year-old male was badly injured. ERC 108 received a call at 07:11:00 hrs. Immediately an ambulance was dispatched with rescue team EMT Gajendra and Pilot Dharmendra.

Enroute EMT advised the caller to keep patient safety and do not move and feed anything orally. As the the scene was overcrowded and the patient was very critical due to multiple injuries including open fracture of the right leg. Ensuring scene safety and maintaining standard precautions, EMT stopped the bleeding by direct pressure using cotton and bandages, once

bleeding was controlled EMT cleaned and dressed the wounds and shifted the patient into the ambulance.

Vitals were measured by EMT, The patient's baseline vitals were, B.P. 120/80, Pulse 85 beats/min, respiration rate 18/Min. and SPO2 96%. EMT Immediately contacted the ERCP G.P. Kushwaha for the online medical direction. As per instruction, EMT promptly started essential pre-hospital care to the victim and injected Diclofenac sodium IM and IV fluid RL 30 drop per minute. EMT did the splinting of the lower extremity at the same time.

EMT shifted the victim to CHC Maharajganj, Raebareli. Medical Officer provided immediately interventions and emergency medications. Due to the criticality of the patient and non-availability of adequate resources at CHC level, Medical Officer advised for inter facility transfer (IFT), Further the victim was shifted to the District Hospital Raebareli with ongoing assessment and management.

The victim was safely handover to the District Hospital Raebareli with proper monitoring. The Victim was found alive and healthy condition after 48 hours of follow up.



REFLECTION BY EMT : GAJENDRA

I followed the advice of ERCP and saved the victim. I would like to thank GVK EMRI for training provided by which I rescued the many patients.

REFLECTION BY PILOT : DHARMENRA

I drove safely and shifted the patient on time. I performed well due to my training in GVK EMRI.



CASE DETAILS

AMBULANCE LOCATION : CHC MAHARAJGANJ, RAEBARELI
 CASE ID : 109418
 DATE : 05/2/2022
 CALL TIME : 07:11 HRS
 ERCP : DR. G.P. KUSHWAHA
 RECEIVING HOSPITAL : D.H. MAHARAJGANJ, RAEBARELI

MEDIA COVERAGE & PATIENT RECEIVING PRE-HOSPITAL CARE IN 108 AMBULANCE



MARCH 2022

A CASE OF BURNS

MARCH 2022

A 35 years old male , Mr. Jeetendra Goundha, a resident of Rajkot, was working near a furnace in a factory and all of a sudden, his clothes caught fire and he suffered multiple body burns. So, one of his co-workers immediately dialed 108 Emergency Response Center and requested for an ambulance.

This case was assigned to the Ambulance located at Kothariya Solvant, District Rajkot manned by EMT Arun Mehta and Pilot Rohit Vala. After collecting the essential case details, they rushed to the patient's residence. While on the way, EMT Ankur instructed caller to sprinkle water on victims burned body parts, try to remove clothes and ornaments but not to pull it if stuck to the body, try to keep patient's environment cool and not to give him anything by mouth. After the preparation of necessary equipments, adequate BSI precautions were taken.

On arrival at scene, Mr. Jeetendra was in an altered state of consciousness with low blood Oxygen saturation level and Pulse Rate, so immediately EMT Ankur opened airway with jaw thrust and started bag valve mask ventilations. EMT Ankur shifted Mr. Jeetendra into the ambulance on spine board with the help of Pilot Rohit. In the ambulance, vitals were assessed which were as follows: Pulse Rate 32 beats/min, Respiration Rate 14 breaths/min, SpO2 75% and Blood Pressure 80/40 mm of Hg.

En-route to the hospital, EMT Ankur continued bag valve mask ventilations with high flow oxygen in proper position and IV line was accessed in both hands. While en-route to the hospital, patient's condition suddenly deteriorated and his Pulse Rate went down drastically to only 22 beats/min and Respiration Rate was 10 breaths/min and so, as per advice of Emergency Response Center Physician Dr. Bhavik, EMT Ankur started Cardio

Pulmonary Resuscitation and Bag Valve Mask Ventilations with high flow oxygen. EMT continued CPR until his vital health parameters improved.

With diligent observation and continuous monitoring, Mr. Jeetendra was rapidly shifted to PDU Civil Hospital, Rajkot. At the time of hospital hand-over, his vital parameters were as follows: Pulse Rate 46 beats/min, Respiration Rate 14 breaths/min, SpO2 83% and Blood Pressure 98/66 mm of Hg.

On 48 hours follow-up, it was reported that Mr. Jeetendra was recovering. Thanks to the dedicated and coordinated efforts of the '108' team that saved precious life.



REFLECTION BY EMT : ANKUR MEHTA

I am really grateful as our case has been nominated to be savior for the first time. It was difficult to provide care to Burns patient. Under guidance and support from ERCP, I was able to handle this emergency and save this patient with the knowledge and skills gained during my training. I really thank 108 GVK EMRI for giving me an opportunity to serve.

REFLECTION BY PILOT: ROHIT VALA

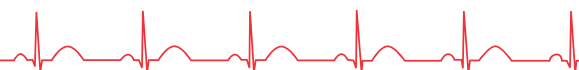I am enjoying every movement working with 108, as my work involves helping the EMT in reviving critical patients as well as giving assurance to their relatives. The patient was very critical, this made me more cautious as any of my driving skills should not interrupt with the continuous care been delivered to the patient by EMT Ankur. I will continue to contribute in my own way in saving each and every precious life.



CASE DETAILS

PATIENT RECEIVING PRE-HOSPITAL CARE IN 108 AMBULANCE

AMBULANCE LOCATION : KOTHARIYA SOLVANT
 CASE ID : 20220200355933
 DATE : 26/02/2022
 CALL TIME : 06:07 HRS
 ERCP : DR. BHAVIK
 RECEIVING HOSPITAL : PDU CIVIL HOSPITAL, RAJKOT



MARCH 2022

A CASE OF RTA

Mr Bhaskar Kalita aged 22 years was on his Motorcycle going to his home from his college at around 3.3.40 pm on 25th March 2022. He was speeding through the village area. Suddenly an over speeding car hit him from the back and the car ran away from the scene. He was thrown hard on the road and was very badly injured. The bystander immediately came to him for help and someone from the crowd called 108.

The call was received by ERO and locating the address of the scene the case was assigned to Chaygaon PHC location of Kamrup Rural District. The team

comprising of EMT Mr. Anil Choudhury and Pilot Mr. Deep Das rushed to the scene. EMT on his initial assessment and Rapid trauma survey found that the victim very badly injured on right hand and got open ulna fracture with multiple abrasion on his face. Mr. Bhaskar Kalita was critically injured with bleeding. EMT and Pilot quickly stop the bleeding at the same time immobilized the victim and shifted to the Ambulance to give the first aid treatment. vitals of the victim were recorded as R.R = 18 bpm, B.P.= 120/80 mm Hg, Pulse=84 bpm, SPO2=98%

According to the advice of ERCP Dr. Anupam Borgohain, EMT cleaned the lacerated part and dressed with sterilized pads and apply splinting on his hand. The vitals of the victim were closely monitored during transportation every five minute and handed over the case to Rampur PHC.



REFLECTION BY EMT : ANIL CHOUDHURY

The tragic situation had high impact on the locals and all were in great fear and agony. As soon we reached the scene there was ray of hope expecting help and support from us. The quick respond that we made and handle the case swiftly impressed a lot.

REFLECTION BY PILOT: DEEP DAS

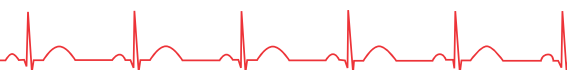
I am happy to be part of this noble project that only deals with the lifesaving process. I take this opportunity to thank GVK EMRI, NHM and Govt of Assam for their beautiful step to introduce 108 Mrityunjoy Service in Assam.



CASE DETAILS

AMBULANCE LOCATION : CHAYGAON PHC
 CASE ID : 20220300175546
 DATE : 25/3/2022
 CALL TIME : 04:00 HRS
 ERCP : ANUPAM BORGHAIN
 RECEIVING HOSPITAL : RAMPUR PHC

PATIENT RECEIVING PRE-HOSPITAL CARE IN 108 AMBULANCE



A CASE OF NEONATAL RESUSCITATION**MARCH 2022**

On 13th March 2022, at 20:22, Neonatal ambulance Margao received a call from ERC saying that there was an IFT from SDH, Ponda to GMC, Bambolim. During conference with on duty doctor, EMT A realized that the baby was in severe birth asphyxia, neonatal seizures, nuchal cord and prolonged labor.

Neonatal ambulance staff reached SDH, Ponda after preheating the incubator. EMT A took the case details from the doctor on duty. Immediately after taking history EMT A found out that b/o Purva, newborn of weight 3 kg, intubated and was unconscious. With the help of pilot EMT A took prompt action to shift

the baby into the ambulance. EMT A then attached the multi para monitor and recorded the vitals of the baby which were as follows:

LOC- unconscious, pulse rate - 130 beats per minute, respiration rate- 44 breaths per minute via bag mask ventilation, SPO2- 80%, Random blood glucose- 78 mg/dl. Skin color- cyanotic, temp-afebrile, condition- moist, capillary refill - 2- 4 sec.

En route to the hospital, baby's heart rate started deteriorating up to 45 beats per minute. On ERCP conference, Dr. Aaron advised to do CPR and continue the treatment advised by duty doctor. EMT A started chest compressions

followed by bag mask ventilation with the ratio of 3:1. Baby's body temperature was maintained via incubator, inj. Adrenaline 1ml/hr via syringe pump was given and inj. Dobutamine in 100ml D10% over 2.5 ml/hr was infused. At the time of handover baby's heart rate increased up to 136 beats per minute and saturation was up to 83%.

EMT A gave reassurance to the baby's relatives and handed over the baby to NICU ward of GMC Hospital, Bambolim. A follow up call post 48 hours confirmed that baby was out of danger and on the path of recovery.

**REFLECTION BY EMT A : SUKLANG KHONGSDIR**

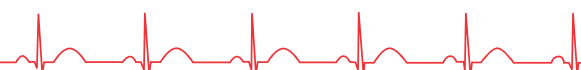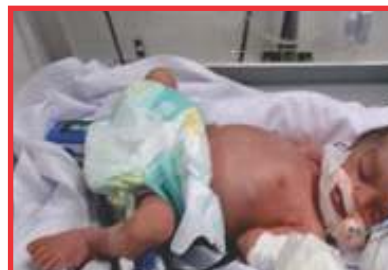We feel satisfied that we could provide good pre hospital care and promptly transport the victim to a health facility and saved his life.

REFLECTION BY PILOT: RAVINDRA GAONKAR

It was indeed a great pleasure to save the new born. I feel glad to be a part of this life saving mission.

**CASE DETAILS****NEWBORN BABY RECEIVING PRE-HOSPITAL CARE IN 108 AMBULANCE**

AMBULANCE LOCATION : MARGAO HOSPCIO
CASE ID : 20220300010041
DATE : 13/03/2022
CALL TIME : 20:22 HRS
ERCP : DR. AARON
RECEIVING HOSPITAL : GMC BAMBOLIM



A CASE OF RTA

MARCH 2022

On 3rd March 2022 at around 02:24 pm, 108-Emergency Response Center (ERC) received a call from a Good Samaritan of Ballari District, who was very frightened by the sudden event and requested for an ambulance urgently. On enquiring about case details by our Emergency Response Officer (ERO) a 45 years old male had multiple minor cuts on his body. ERO assigned the nearest available ambulance Ballari DH location manned with EMT Mantesha and Pilot Sharanappa. The crew reached the incident location which was 20 km away within. On reaching the location and enquiring the history of the incident, it was understood that the victim was on bike driving towards the bypass . During this

processes an oncoming lorry from the opposite direction hit the bike.

EMT Mantesha realized the emergency condition and asked the bystander & Pilot to support in shifting the victim into ambulance to prevent further injury. Victim was shifted into ambulance with the help of scoop stretcher. During the assessment victim was found in unconscious state associated with a wide irregular laceration with bleeding on right side of head & a closed left femur fracture masked with multiple abrasions. A laceration was on left arm .Splinting was applied. All precautionary measures were followed. IV line was accessed and started IVF-RL fast flow .

Base line vitals were recorded, BP-100/60mm of Hg, Pulse-126/bpm, RR-16 breaths/min, SPO2-94%, victim was diaphoretic & unconscious. On consultation with ERCP Dr.Sanjay Oxygen was started at 12 lts/min. Victim was shifted to VIMS hospital Ballari. Doctors appreciated EMT & Pilot for their presence of mind and the accurate pre hospital management which was given to the victim at scene & in the ambulance en route before reaching The Hospital.

Patient relatives showered their gratitude towards our ambulance team.



REFLECTION BY EMT : MANTESHA A

The case was a very critical RTA case & my first experience to deal victim with such severe injuries and I was very nervous and thought it would be difficult to handle here as the crowd was huge & forcing us to shift the victim and move the ambulance. I felt very satisfied for saving life of a victim who suffered severe bleeding injuries. I got good support from Pilot Sharanappa and I am proud to be associated with GVK EMRI.

REFLECTION BY PILOT : SHARANAPPA

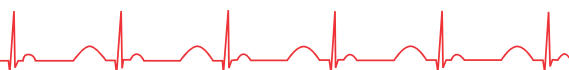
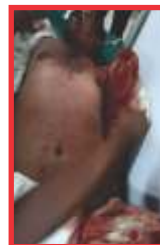I am immensely proud to have saved a life & it was my most memorable case I have ever came across. This was my first encounter in my service to deal with such incidence. I am proud to be associated with GVK EMRI.



CASE DETAILS

AMBULANCE LOCATION : BALLARI DH
 CASE ID : 235718
 DATE : 30/03/2022
 CALL TIME : 02:24 HRS
 ERCP : DR. SANJAY
 RECEIVING HOSPITAL : VIMS HOSPITAL BALLARI

PATIENT RECEIVING PRE-HOSPITAL CARE IN 108 AMBULANCE



MARCH 2022

A CASE OF DELIVERY

Under the care of Kaniv 108 ambulance staff, a tribal woman gave birth at home. At Kalpetta Puzhamudi Padapuram Colony, Aji's wife Maya (26) delivered a baby girl. Maya's family informed the Munderi Primary Health Center staff about Maya's labor pains around noon on 05 March 2022. They rushed to the scene and called Kaniv108 Ambulance to transport Maya to the hospital. A message from the control room was immediately conveyed to Kaniv 108 Ambulance at the Kalpetta General Hospital. Upon receiving this information,

ambulance Pilot Shabin PC and EMT Dhanya Thomas rushed to the scene. The ambulance team reached Maya with a stretcher by walking for about a kilometer as it was inaccessible to vehicles. EMT Dhanya examined Maya and determined that she couldn't be transferred to an ambulance without giving birth. At 12.30 pm, Maya gave birth to a baby. By separating the umbilical cord, EMT Dhanya rendered post delivery care to the mother and new born care to the baby. Mother and the baby were then transported on a stretcher to an ambulance by 108 crew and

health workers. The two were rushed to the hospital by ambulance Pilot Shabin to Kalpetta GH. Relatives say the two are doing fine.

On 48 hours follow up, both mother and baby was found alive and discharged from the hospital.



REFLECTION BY EMT : DHANYA THOMAS

I am glad that the lives of mother and baby are safe

REFLECTION BY PILOT: SHABIN PC

I am glad that the lives of both mother and child are saved by us.



CASE DETAILS

AMBULANCE LOCATION : KALPETTA GH
 CASE ID : 20220200123907
 DATE : 05/03/2022
 CALL TIME : 12:07 HRS
 RECEIVING HOSPITAL : KALPETTA GH

MEDIA COVERAGE



A CASE OF ASSAULT

MARCH 2022

There was a misunderstanding in the family of the 23 years old Aibashisha Kurbah between her elder brother and her mother. On the 6th March, 2022 there was a heated argument between the two. Aibashisha Kurbah, could not bear that such things should go on in her beloved family. With a hope to calm down the situation, she went to intervene and request her two family members to stop. What followed was that she was hit by her very own elder brother with a sharp object on her back. Her brother ran away after the incident leaving her bleeding, dying and waiting for help. On seeing her condition, the other family members dialed the number 108.

After receiving the information from the patient party, the ERO immediately at 18:30 PM assigned the case to the 108-ambulance based at Umsning CHC. EMT Nisha Shangpliang, EMT on duty and Pilot Richmond Rapsang, Pilot on duty quickly rushed to the scene at Umiarong for attending the case. On reaching the scene, the ambulance team went to check the patient. The patient was still conscious. But she could not move her areas below her waist. She was hit on her back, right in the region just in the pelvic bone. A huge cut is visible with profuse bleeding. Wound care was done. Spinal immobilization was done. Pelvic binder was also done though the patient complains of

pain. The EMT, after assessment of the patient called for Online Medical Direction and received instruction from Dr J Nongtdu. Oxygen was given at 6 liters per minute. Injection diclofenac was given. The patient was transported to Umsning CHC but due to the criticality of the case, the patient was shifted to Shillong Civil Hospital after stabilization in Umsning CHC.

On 48 hours follow up, the patient is still in hospital but greatly improved in condition.



REFLECTION BY EMT : NISHA SHANGPLIANG

This case was scary and challenging. Thanks to the ERCP Advice, it helps us to handle this case with confidence

REFLECTION BY PILOT: RICHMOND RAPSANG

I am happy that we were able to help this lady and her family members who remember only to call 108 during this difficult time.



CASE DETAILS

AMBULANCE LOCATION : UMSNING BASE
 CASE ID : 20220000020562
 DATE : 06/03/2022
 CALL TIME : 18:30 HRS
 ERCP : DR. J NONGTDU
 RECEIVING HOSPITAL : SHILLONG CIVIL HOSPITAL

PATIENT PHOTOGRAPH



MARCH 2022

A CASE OF HANGING

On 29th March 2022, our Emergency Response Centre received a call for a 33 years old male who attempted to hang himself with a rope in his house. One of his family members witnessed the incident and called his family immediately for help. The Victim was removed from the rope and he found unconscious. Immediately our Emergency Response Officer assigned the case to Suraman gamam location ambulance for the emergency support.

On reaching the scene, BSI precautions were followed by the EMT. On assessment, the victim was found unresponsive with no breathing and palpable

carotid pulse. The victim was ventilated with BVM. The victim's neck was strangulated by the rope, therefore ligature marks were present in his neck. Cervical collar was applied and airway was maintained. After stabilization of Airway, Breathing and circulation, the victim was safely shifted in to the ambulance by the help of Spine Board. The vital parameters were checked and observed as bradycardia, hypoxia, un recordable blood pressure, hypoxia, dilated pupils and hypothermia. BVM connected to 15 lit of oxygen to ventilate the victim and IV line was secured.

En route to the hospital, our EMT obtained the ERCP advised. As advice by ERCP, IV fluids (RL) and medications (Inj. Adrenaline) administered and the victim's vitals were monitored till the ambulance reached the hospital. En route to the hospital, the victim's vitals were improved. The victim was safely shifted to the Government Medical college and Hospital, Coimbatore for the further management.

After 48 hours follow up, the victim was found to be out of danger in Intensive Care Unit.



REFLECTION BY EMT : KANNAN

It was a critical case. I have provided the appropriate pre-hospital care to save the victim's life. I am proud to be an Emergency Medical Technician of 108 ambulance services.

REFLECTION BY PILOT: ASHOK KUMAR

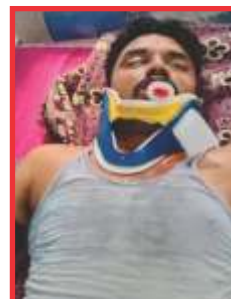I assisted the EMT and I moved the ambulance quickly to the hospital.



CASE DETAILS

PATIENT RECEIVING PRE-HOSPITAL CARE IN 108 AMBULANCE

AMBULANCE LOCATION : SURAMANGALAM
 CASE ID : 855554
 DATE : 29/03/2022
 CALL TIME : 14:29 HRS
 ERCP : DR. SHIVANI
 RECEIVING HOSPITAL : GOVERNMENT GENERAL HOSPITAL, SALEM.



A CASE OF RTA

MARCH 2022

On 20th March 2022, at 11:33 hrs. A road traffic accident was reported on Jangoan main road of old Warangal district. Mr. Manohar Rajput, after consuming alcohol, was returning back from Jangoan on his bike to his home town at Devaruppala Mandal Head Quarters of Jangoan District. Under the influence of alcohol, he was going at high speed, lost control and hit the divider of the main road. In this incident, he sustained serious injuries, the people who were passing by stopped and found him with serious injuries and semi-conscious condition, also he was not wearing the helmet, called 108 services for helping and caring for the victim. They also informed the Police.

On reaching the scene, EMT Mr. Yadagiri, performed a rapid trauma assessment, found that Mr. Manohar Rajput aged 43, semi-conscious, deep bleeding laceration of the occipital region of the head and also had multiple abrasions all over the body. EMT with the help of Pilot Mr. Ramesh, controlled the bleeding by following hemorrhage controlling techniques, provided the wound care and applied C-

Collar for immobilization of cervical spine, shifted the victim into the ambulance by using the scoop stretcher and initiated high flow oxygen. Baseline vital signs were recorded; BP 110/70 mm Hg, Pulse rate 98/min and Respiratory rate 24/min. ERCP Dr. Sugunadhar was contacted, after explaining the details, on his advice IV fluids initiated, Injection Rantac, Injection Tramadol IM were given. Later he also informed about the cash bundles and gold ornaments found in the victim's bag pack. He found the mobile phone of victim in same bag, called his relative number and informed about accident.

With close monitoring, the victim was transported to the Area Hospital of Jangoan (Old Warangal District), for necessary care and management. On reaching the hospital, some of the victim's family members were already there. Our ambulance staff handed over the bag pack to his brother Mr. Babulal Rajput in the presence of the other family members, hospital staff and Police personnel present in the hospital. His brother informed all the people around saying that the value of gold

ornaments is roughly of 300 grams and cash bundles of Rs. 2,47,000/-. All the family members and others highly appreciated for our ambulance staff for the honesty.

Our Associates learnt from later follow-up and further recent enquiry from the Hospital doctors team, had given the information that victim Mr. Manohar Rajput, after stabilization of his immediate condition and primary care, the family members decided to shift the victim to a private Hospital by private ambulance to Secunderabad for further surgical advanced care.

Later our Telangana State Head Operations Mr. MA Khalid, Program Manager Mr. Naseeruddin Shaik and all others of GVK EMRI highly appreciated our 108 Jangoan Ambulance Team EMT Mr. Yadagiri and Pilot Mr. Ramesh for all their sincere efforts in handling this RTA case and their honesty.



REFLECTION BY EMT : KOMMU YADAGIRI

"As compared to my previous experience of RTA cases, this case was very interesting, the victim was found semi-conscious on the Jangoan main road with head Injury and other injuries. On reaching the scene, immediately with help of the Pilot Mr. Ramesh followed all the Pre-Hospital Care protocols. Along with victim we found a bag pack with valuable items. We have saved the precious life of the victim. We felt very happy that when the victim family members, receiving hospital personnel and our GVK EMRI higher officials appreciated our timely services for helping the victim by providing proper care and handing over of the valuable items (Cash Bundles and Gold ornaments) to victim family members (Brother Mr. Babulal Rajput)."

REFLECTION BY PILOT: RAMESH SATLA

"It was great satisfaction for helping the victim in this critical condition, after shifting into the ambulance, transported safely to the nearest Hospital. In follow up, we informed that the victim is recovered from Yashoda Hospital of Secunderabad and doing his regular activity. we personally went to his home town and met him, felt very happy, satisfied, when the victim family members appreciated our good services and sincere efforts by providing an appreciation letter to us."

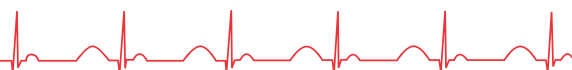

MEDIA COVERAGE

HANDING OVER OF VICTIM BELONGINGS TO MR. BABULAL RAJPUT (BROTHER) PHOTOGRAPH VICTIM RECOVERY AND APPRECIATION LETTER PHOTOGRAPHS

CASE DETAILS

AMBULANCE LOCATION : CHC JANGOAN
 CASE ID : 20220001440615
 DATE : 20/03/2022
 CALL TIME : 11:33 HRS
 ERCP : DR. SUGUNADHAR
 RECEIVING HOSPITAL : AREA HOSPITAL JANGOAN



MARCH 2022

A CASE OF RTA

This was a road traffic accident where two bikes were collapsed with each other and four people got injured. Among four, one 21 year old girl was badly injured. ERC 108 received a call for case at 03:31:00 hrs. Immediately an ambulance was dispatched with rescue team EMT Mr. Pradeep and Mr. Pilot Deepak.

Ensuring the B.S.I. precautions EMT immediately moved for the scene. Enroute EMT instructed the caller to stop the blood by direct pressure. EMT arrived at scene and found the patient in very critical with head injury and multiple wounds on the body, EMT along with Pilot shifted the patient immediately to ambulance maintaining the spinal immobilization on spine board. On initial assessment patient was found to be semiconscious EMT started the

ventilation with high flow oxygen. EMT stop the bleeding by cotton and bandage with direct pressure, once bleeding was controlled EMT did the cleaning and proper dressing of wounds.

After arriving to scene to the nearest CHC EMT shifted the victim to the hospital staff of CHC Sikara, Jaunpur. Medical Officer provided immediate interventions and emergency medications Due to criticality of the patient and non-availability of resources at CHC, Medical Officer called Emergency Response Center and requested for inter facility transfer (IFT). Further the victim was referred to the District hospital Jaunpur.

Vitals were measured by EMT, Patient's baseline vitals were, B.P.

100/60, Pulse 62 beats/min, respiration rate 18/Min. and SPO2 91%. EMT Immediately contacted the ERCP G.P. Kushwaha for the online medical direction. As per instruction EMT promptly started essential pre hospital care to the victim and injected Diclofenac sodium IM and IV fluid RL 30 drop per minute. Victim was safely handover to the District Hospital Jaunpur with proper monitoring.

After 48 hours follow up, victim was found alive and healthy.



REFLECTION BY EMT : PRADEEP KUMAR

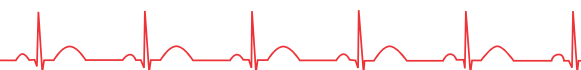
I would like to thank to my training and refresher training where I rescued one more patient. Thank you GVK EMRI.

REFLECTION BY PILOT : DEEPAK KUMAR
I did my duty well and safely shifted the patient to the District Hospital. Thank you GVK EMRI for providing the training and refresher training time to time.



CASE DETAILS PATIENT PHOTOGRAPH, MEDIA COVERAGE AND APPRECIATION LETTER

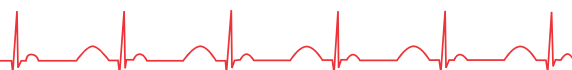
AMBULANCE LOCATION : CHC SIKARA, JAUNPUR
CASE ID : 20221030544736
DATE : 23/03/2022
CALL TIME : 03:31 HRS
ERCP : DR. G. P. KUSHWAHA
RECEIVING HOSPITAL : D.H. JAUNPUR



Air Ambulance services Inaugurated by Hon'ble Minister of Civil Aviation Government of India Shri. Purnesh Modi and Hon'ble Gujarat State Minister of Civil Aviation Shri. Arvindbhai Raiyani on 21st March 2022



Hon'ble Health Minister of Telangana Shri. T. Harish Rao Inaugurated 2 New 108 Ambulances on 30th March 2022



GVK EMRI Director Shri. K. Krishnam Raju's Interaction with Shri. Dr. Himanta Biswa Sarma, Hon'ble Chief Minister of Assam on 20th March 2022



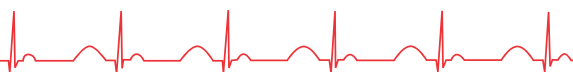
73rd Republic Day Celebrations



Hon'ble Chief Minister of Tamil Nadu Shri. M.K. Stalin launched additional 188 New 108 Ambulance on 23rd February 2022



55 New BLS Ambulances Inaugurated by Government of Rajasthan and GVK EMRI Team on 10th January 2022





GVK EMERGENCY MANAGEMENT AND RESEARCH INSTITUTE

Devar Yamzal, Medchal Road, Secunderabad - 500 078 Telangana, India.

Tel : + 91 40 2346 2600, 2346 2602 - Fax 2346 2178

www.emri.in

Follow on :



<https://www.facebook.com/GVKEMRIOnline/>



<https://www.linkedin.com/company/emri/>



<https://twitter.com/GVKEMRIOnline>



https://www.instagram.com/gvk_emri



<https://www.youtube.com/channel/UC1a8-nD0E6pJ-gQrImqcyw>